



REVIEW ARTICLE

Positron emission tomography in ischemic heart disease



Beatriz Saldanha Santos^{a,*}, Maria João Ferreira^b

^a Serviço de Cardiologia, Hospital Distrital de Santarém, Santarém, Portugal

^b Faculdade de Medicina, Centro Hospitalar e Universitário de Coimbra, Universidade de Coimbra, Coimbra, Portugal

Received 21 October 2017; accepted 3 February 2019

KEYWORDS

Positron emission tomography/
computed tomography;
Ischemic heart disease;
Perfusion imaging;
Myocardial viability

Abstract Non-invasive assessment of ischemic heart disease remains a challenging task, even with a large armory of diagnostic modalities. Positron emission tomography (PET) is an advanced radionuclide technique that has been available for decades. Originally used as a research tool that contributed to advances in the understanding of cardiovascular pathophysiology, it is now becoming established in clinical practice and is increasingly used in the diagnosis and risk stratification of patients with ischemic heart disease. PET myocardial perfusion imaging has a mean sensitivity and specificity of around 90% for the detection of angiographically significant coronary artery disease, and is also highly accurate for assessing the prognosis of patients with ischemic heart disease. Depending on the radiotracer used, it can provide information not only on myocardial perfusion but also on myocardial metabolism, which is essential for viability assessment. The potential of this imaging technique has been further increased with the introduction of hybrid scanners, which combine PET with computed tomography or cardiac magnetic resonance imaging, offering integrated morphological and functional information and hence comprehensive assessment of the effects of atherosclerosis on the myocardium. The scope of this review is to summarize the role of PET in ischemic heart disease.

© 2019 Sociedade Portuguesa de Cardiologia. Published by Elsevier España, S.L.U. This is an open access article under the CC BY-NC-ND license (<http://creativecommons.org/licenses/by-nc-nd/4.0/>).

PALAVRAS-CHAVE

PET-CT;
Doença cardíaca isquémica;
Perfusão miocárdica;
Viabilidade miocárdica

Tomografia de emissão de positrões na doença cardíaca isquémica

Resumo A multiplicidade de técnicas de diagnóstico existentes, para avaliação da doença cardíaca isquémica, pode representar um desafio na escolha da mais adequada se não forem conhecidas as características de cada uma, nomeadamente, potencialidades, disponibilidade, riscos inerentes e custos. A tomografia de emissão de positrões (PET) é uma técnica de imagem com várias décadas de evolução. Usada inicialmente no campo da investigação, contribuiu para avanços significativos na compreensão da fisiopatologia cardiovascular. Atualmente, tem um papel cada vez mais relevante no diagnóstico e estratificação de risco da doença cardíaca

* Corresponding author.

E-mail address: santos.beatrizsgp@gmail.com (B.S. Santos).

isquêmica. A imagem de perfusão miocárdica por PET tem uma especificidade e sensibilidade médias de 90% para a detecção de doença coronária arterial significativa. Dependendo do radiofármaco escolhido, a informação poderá versar sobre a perfusão miocárdica mas também sobre o seu metabolismo, essencial, na apreciação da viabilidade. O potencial desta técnica de imagem aumentou com a introdução das câmaras híbridas que a combinam com a tomografia computadorizada ou com a ressonância magnética cardíaca. Estas integram informação morfológica e funcional, fornecendo uma avaliação completa das consequências da aterosclerose no miocárdio. Com esta revisão pretendeu dar-se uma panorâmica da aplicação da PET no âmbito da doença cardíaca isquêmica.

© 2019 Sociedade Portuguesa de Cardiologia. Publicado por Elsevier España, S.L.U. Este é um artigo Open Access sob uma licença CC BY-NC-ND (<http://creativecommons.org/licenses/by-nc-nd/4.0/>).

Introduction

Recent guidelines recommend that patients with ischemic heart disease (IHD) have their care driven by risk assessment.¹ Structural and functional information provided by different imaging techniques aids the physician in assessing different aspects of the disease. The recent shift in the management of IHD from an anatomical to a functional gold standard has highlighted the importance of functional imaging techniques.

Positron emission tomography (PET) is a nuclear medicine imaging technique that uses radiotracers to produce images of radionuclide distribution with an exterior detector system.² These tracers can provide information on a wide range of biological pathways by non-invasive methods, using physiological substrates labeled with positron-emitting radionuclides. PET enables the assessment of flow-limiting IHD by analyzing myocardial perfusion, function and metabolism.

The role of contemporary radionuclide myocardial perfusion imaging (MPI) in the diagnosis and management of IHD is well established. Although qualitative or semi-quantitative assessment of regional perfusion is most used in clinical practice, it has limitations in determining the extent of IHD, especially in patients with multi-vessel disease.^{3,4} Another limitation of semi-quantitative perfusion assessment that is applicable to all imaging techniques is its inability to delineate the extent and severity of diffuse atherosclerosis and microvascular dysfunction.

Quantitative PET measurement of myocardial blood flow (MBF) in absolute terms (ml/g/min) potentially represents a paradigm shift in the assessment and management of patients with IHD.

Although PET is considered the current gold standard for quantitative non-invasive assessment of myocardial perfusion and viability, various factors have hindered its widespread clinical application, including limited availability of scanners and tracers and high costs.⁵

Positron emission tomography

Principles of positron emission tomography imaging

Like single-photon emission computed tomography (SPECT), PET relies on external detectors to image the distribution of radiotracers with known characteristics labeled with positron-emitting isotopes. Positrons are the antimatter counterpart of electrons, and when the two interact, the electron-positron annihilation event^{6,7} results in two 511-keV gamma photons being emitted simultaneously at approximately 180° to each other that are sensed by a detector ring.⁸ Coincidence detection without the need for physical collimators is one of the advantages of PET over SPECT. Although SPECT remains the most widely employed modality in most centers with nuclear cardiac imaging, it has important limitations that PET can overcome. [Table 1](#) summarizes the characteristics of PET and SPECT.

Radiotracer characteristics and limitations

PET imaging reflects cardiac physiology rather than anatomy. The information obtained depends on the radioactive nuclides used and their imaging characteristics. Therefore, selection of the nuclide depends on multiple factors besides the aim of the PET imaging program. [Table 2](#) compares the characteristics of the different tracers used.

Myocardial perfusion imaging

Four radiotracers are mainly used for myocardial perfusion imaging: ¹⁵O-labeled water (H₂¹⁵O), ¹³N-labeled ammonia (¹³NH₃), rubidium-82 (⁸²Rb), and an ¹⁸F-labeled PET perfusion tracer, ¹⁸F-BMS-747158-02 (flurpiridaz).⁹ Each has specific properties that make one preferable over another in individual situations.

Myocardial metabolism imaging

Under normal conditions, oxidative phosphorylation is the principal pathway involved in energy production in cells.

Table 1 Characteristics of single-photon emission computed tomography and positron emission tomography.

	Cardiac PET	Cardiac SPECT
Availability	Limited	Widespread
Photon detection	Coincidence detection with crystals positioned 360° around the patient	Detection of single photons Dual-headed gamma cameras that rotate around the patient (most common); novel multi-headed solid-state cameras positioned 180° around the patient
Collimation	None	Required
Attenuation correction	More accurate	Less accurate
Spatial resolution	4-7 mm	10-15 mm
Protocol	<1 hour	Up to 5 hours on 1 or 2 days
Radiation exposure	<5 mSv	7-10 mSv
Myocardial perfusion images	Absolute quantification possible	Usually semi-quantitative
Hybrid with CT	Yes	Yes
Hybrid with MRI	Yes	No

CT: computed tomography; MRI: magnetic resonance imaging; PET: positron emission tomography; SPECT: single-photon emission computed tomography.

Table 2 Characteristics of tracers used in positron emission tomography.

	Myocardial perfusion tracers				Myocardial metabolism tracers
	¹³ NH ₃	⁸² Rb	H ₂ ¹⁵ O	¹⁸ F flurpiridaz	FDG
Production method	Cyclotron	Generator	Cyclotron	Cyclotron	Cyclotron
On-site cyclotron	Required	Not required	Required	Not required	Not required
Half-life	9.97 min	76 s	123 s	110 min	119 min
Kinetics	Metabolically trapped in myocardium	Freely diffusible, metabolically inert	Metabolically trapped in myocardium	Metabolically trapped in myocardium	Metabolically trapped in myocardium
Scan duration	20 min	6 min	6 min	20 min	10-30 min
Gating /LV function	+	+	-	+	X
Radiation dose	~1 mSv	~3 mSv	~ 0.4 mSv	~ 4 mSv	X
Quantification	Good	Moderate	Excellent	Very good	X

¹³NH₃: ¹³N-labeled ammonia; FDG: ¹⁸F-2-fluoro-2-deoxyglucose; ⁸²Rb: rubidium-82; H₂¹⁵O: O¹⁵-labeled water; LV: left ventricular.

In a normal heart, the major source of adenosine triphosphate (ATP) is oxidation of free fatty acids, rather than of carbohydrate.⁷ During ischemia, reversible metabolic adaptation will occur to enable myocytes to survive in a low-oxygen environment. Mitochondrial oxidation is suppressed and anaerobic metabolism can proceed. Under these circumstances, exogenous glucose uptake and glycogen breakdown are increased, glycolysis is stimulated, and ATP can be produced from the anaerobic catabolism of glucose with concomitant formation of lactate.¹⁰

In view of the myocardium's use of exogenous glucose, PET imaging uses ¹⁸F-2-fluoro-2-deoxyglucose (FDG) to trace glucose uptake. FDG is a glucose analogue that is transported into the myocyte by the same trans-sarcolemmal carriers (GLUT-1 and GLUT-4) as glucose and phosphorylated to FDG-6-phosphate by hexokinase.⁹ It is not further metabolized or used in glycogen synthesis or aerobic glycolysis.

Because dephosphorylation and return of the radiotracer to the blood is minimal, it becomes metabolically trapped in the myocardium, permitting PET imaging of regional glucose uptake that reflects overall cell glucose uptake. FDG uptake may be increased in hibernating but viable myocardium; uptake in regions with reduced blood flow at rest has become a marker of hibernation.¹¹ FDG is produced by a cyclotron and decays with the emission of a positron with a half-life of 110 min. The 110-min half-life of FDG gives sufficient time for synthesis and purification, with commercial distribution within a radius of several hours' travel from the production site.⁸

Nevertheless, the diagnostic quality of FDG imaging is critically dependent on hormonal milieu and substrate availability. Images with FDG depend on patient preparation, as described in the imaging guidelines for PET.⁸

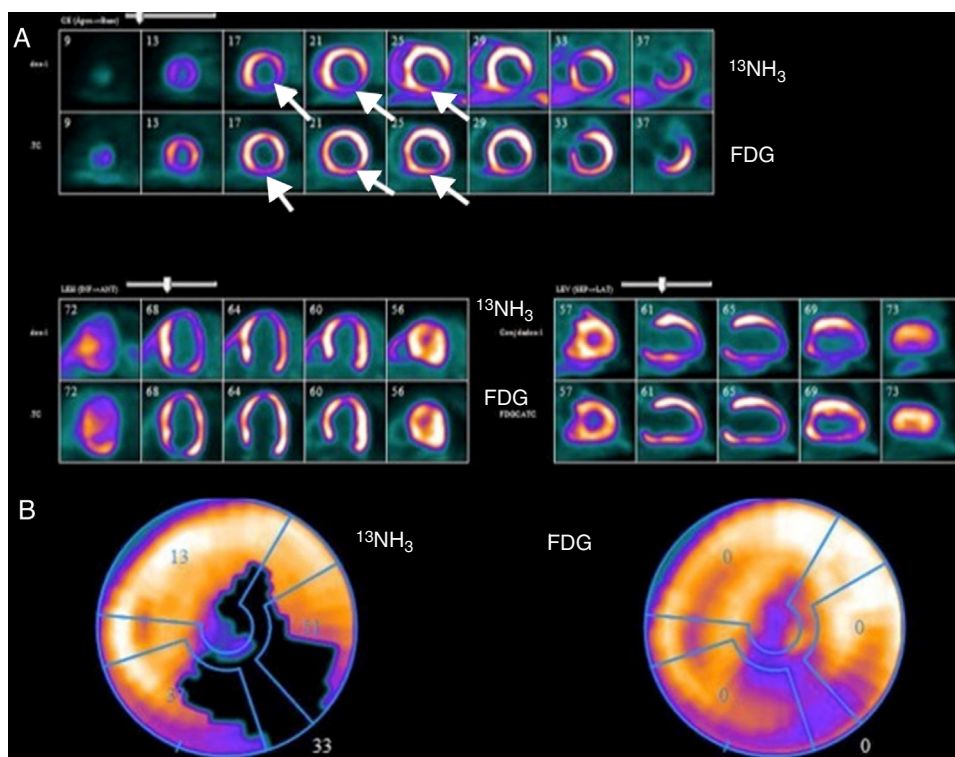


Figure 1 Example of assessment of myocardial viability with positron emission tomography imaging. (A) Top rows: ^{13}N -labeled ammonia ($^{13}\text{NH}_3$) is used as a tracer of myocardial blood flow at rest in short-axis images starting at the apex and moving toward the base of the heart (upper image), horizontal long axis (lower left) and vertical long axis (lower right). Myocardial perfusion is markedly decreased in the apical, inferior and inferolateral regions (white arrows); Bottom rows: ^{18}F -2-fluoro-2-deoxyglucose (FDG) is used as a tracer of myocardial glucose metabolism. FDG uptake is enhanced relative to blood flow, demonstrating a pattern of perfusion-metabolism mismatch (white arrows) in the abnormally perfused myocardial regions, indicative of viable or hibernating myocardium; (B) polar map of viability study. The left polar map plot displays the extent of the rest perfusion defect (black area); the right polar map plot shows FDG uptake in the rest perfusion defect area indicating metabolic viability. Image source: Instituto das Ciências Nucleares Aplicadas à Saúde (ICNAS).

Positron emission tomography in the assessment of myocardial perfusion and viability

Perfusion assessment

The clinical scenario and the capabilities of the technique influence the choice of cardiac imaging test. The following sections discuss the use of cardiac PET in the assessment of IHD at different stages and clinical presentations.

Interpretation of perfusion data

Similarly to SPECT, in clinical practice PET perfusion images are most commonly graded visually in a qualitative manner. Qualitative defect estimation should be performed by describing the location of the abnormal segments involved and their extent in the left ventricle. The extent of the defect may also be qualitatively described as small (5-10% of the left ventricle), medium (10-20%), or large (>20%).⁸ Defect severity is typically expressed qualitatively as mild, moderate or severe depending on its similarity to background tracer activity.

Stress and rest myocardial perfusion image sets are compared in order to determine the presence, extent and severity of stress-induced perfusion defects and to determine whether such defects represent regions of myocardial ischemia or infarction. Regions with only stress-induced defects represent ischemia. Perfusion abnormalities on stress images which remain unchanged on rest images are termed fixed defects and most often represent areas of prior myocardial infarction (MI). Areas of partial reversibility represent the presence of both scar and ischemia (Figure 1).

Absolute quantification of myocardial blood flow

In addition to qualitative and semi-quantitative grading, PET also enables absolute quantification of perfusion. Quantitative blood flow approaches offer an objective interpretation that is inherently more reproducible than visual analysis. Blood flow can be assessed globally and regionally. When epicardial coronary arteries are narrowed by atherosclerotic disease, coronary autoregulation attempts to normalize MBF by reducing the resistance of distal perfusion beds at the arteriolar level, thus maintaining myocardial oxygen supply.¹² MBF can be estimated using various techniques, including coronary catheterization with a Doppler flow wire, but all of these techniques are invasive and thus have

limitations for clinical practice.^{13,14} PET has become the non-invasive imaging modality of choice for the quantification of MBF.

Resting MBF is the absolute quantity of blood that the myocardium receives per minute per gram of tissue under baseline conditions. MBF conceptually refers to the measurement not just of epicardial flow, but also microvascular flow and function.¹⁵ MBF values in normal individuals at rest range between 0.6 and 1.3 ml/min/g (mean 0.98 ± 0.23 ml/min/g).^{16,17}

Hyperemic MBF represents the maximum blood flow that can be supplied to the heart during maximum vasodilation of the coronary vascular bed. This is usually achieved through pharmacologically induced stress.¹⁸

Myocardial flow reserve (MFR) is the ratio of stress to resting MBF. MBF and MFR values obtained by PET are not the same as those from invasive measurement of epicardial coronary flow reserve (CFR) or fractional flow reserve (FFR), although they are closely linked.^{6,19} MFR, unlike FFR, assesses the combined effects of stenosis and microcirculation, but cannot differentiate the effects of either independently. It is thus possible to have discordant MFR and FFR values in the case of a dominant focal lesion with minimal microcirculatory disease, or when there is diffuse epicardial disease combined with severe microcirculatory disease.^{19,20}

There is currently limited information on the optimal threshold to distinguish pathological from normal hyperemic MBF and MFR.²¹ It is accepted that MFR values can be interpreted as follows:

MFR >2.3 indicates low risk (assuming that there is no lower regional value)^{8,18};

MFR <1.5 suggests significantly decreased flow reserve (in the absence of concomitant increased resting MBF), and is associated with increased cardiac risk.^{8,18}

These values were recently confirmed by a multicenter study that established an optimal threshold of 2.3 ml/min/g for hyperemic MBF and 2.5 for MFR compared to invasive FFR measurements.²² Alternatively, MBF values can be interpreted on a continuous scale for diagnostic and prognostic purposes as well as for subsequent clinical decision-making.²¹

It is important to assess both hyperemic MBF and MFR in all subjects. In addition, like most other imaging

parameters, MBF should be considered as supplementary, in conjunction with other clinical characteristics and image findings, when used for diagnosis or to guide patient management. Table 3 summarizes the potential applications of absolute flow quantification.

In conclusion, absolute quantification of myocardial blood flow expands the scope of conventional relative MPI from identifying only end-stage epicardial IHD to the earlier identification and characterization of abnormalities in coronary endothelial function and subclinical stages of IHD (microvascular dysfunction).¹⁵

Diagnostic accuracy of positron emission tomography in ischemic heart disease

The majority of studies exploring the diagnostic accuracy of PET perfusion imaging for detection of IHD have been conducted with static uptake of ⁸²Rb and ¹³NH₃.²¹ Compared with SPECT, perfusion imaging using PET consistently yields higher diagnostic accuracy.²³⁻²⁵ An early review based on a pooled analysis of 79 studies with SPECT of nearly 9000 patients reported a mean sensitivity of 86% and mean specificity of 74% for detecting >50% angiographic stenosis, with improved specificity using attenuation correction methods.²⁶ With PET perfusion imaging, the reported mean sensitivity reached 90% and the mean specificity 89% for detecting >50% angiographic stenosis, as derived from a pooled analysis of nine studies of almost 900 patients.²⁷ Although many of these studies had important limitations (most were small retrospective series, using older two-dimensional PET systems, and most did not quantify MBF), more recent data support the same conclusions.^{28,29} Two recent meta-analyses demonstrated that PET MPI is superior to SPECT MPI.^{25,30} Sensitivity and specificity for PET in these meta-analyses ranged from 90% to 93% and 81% to 88%, respectively.

Results of the Prospective comparison of Cardiac PET/CT, SPECT/CT perfusion imaging and CT coronary angiography with Invasive Coronary angiography (PACIFIC) trial were published in 2017.³¹ This was the first head-to-head comparison of the most commonly used non-invasive techniques against FFR. All modalities were compared and the investigators found that PET was more accurate (85%) than cardiac computed tomography angiography and SPECT for diagnosing coronary ischemia. Although the diagnostic accuracy of PET

Table 3 Potential applications of absolute flow quantification.

Application	Description
Early atherosclerosis	Assessment of microvascular dysfunction in diabetes, hypertension, metabolic syndrome, etc.
Advanced atherosclerosis	Improved detection of multivessel disease
Non-atherosclerotic microvascular disease	Evaluation of hemodynamic significance of stenosis
	Stable angina or ACS with normal coronary angiogram
	Transplant vasculopathy
Determination of prognosis	Dilated cardiomyopathy
	Hypertrophic myopathy
	Evaluation of therapies

Adapted from Ohira et al.,¹⁵ Gould et al.,¹⁹ Schelbert et al.,⁶⁷ and Camici et al.⁶⁸
ACS: acute coronary syndrome.

imaging was similar to that reported in previous studies, this was the first head-to-head comparison of anatomic and functional imaging techniques in suspected IHD.

Measurement by PET of myocardial perfusion in absolute units further improves its diagnostic accuracy. Testing has been less extensive for quantitative perfusion imaging; however, there is growing evidence of its superiority over static uptake image grading.³²⁻³⁵ Patients with multivessel disease (i.e. balanced ischemia), early stage blood flow impairment or microvascular disease, and those with high body mass index could benefit most from this quantitative assessment.^{21,33}

Although its cost-effectiveness in high-throughput centers has been demonstrated, the clinical utility of PET is still constrained by high upfront cost and low availability compared with SPECT.³⁶

Prognostic value of positron emission tomography in ischemic heart disease

PET MPI has been shown to have prognostic value in the context of both normal and abnormal scans, providing incremental risk information in patients with known or suspected IHD. The extent and severity of PET-derived perfusion defects have also been shown to provide valuable prognostic information beyond traditional cardiovascular risk factors.³⁷⁻³⁹ A normal scan indicates low risk (<1% annual cardiovascular [CV] event rate) while an abnormal scan indicates a worse prognosis (>4.2% annual event rate), the risk increasing with the extent of ischemia and the severity of the findings.³⁷⁻³⁹ Furthermore, the integration of perfusion and functional imaging enables assessment of rest left ventricular (LV) ejection fraction (LVEF), stress LVEF and LVEF reserve (stress LVEF - rest LVEF) as well as LV volumes, providing incremental prognostic value.^{40,41} Even in the presence of angiographically significant IHD, normal findings on stress MPI are generally associated with a low risk of CV events (around 1% per year).⁴²

As well as LVEF, LVEF reserve is also a marker of extensive anatomic obstructive IHD (providing higher sensitivity than perfusion data alone, 50% vs. 79%) and an independent and incremental marker for patient outcome.⁴³ Even after accounting for differences in clinical factors and perfusion findings, patients with LVEF reserve <0 have a higher annual risk of coronary events (2.1% vs. 5.3%, $p < 0.001$) and all-cause death (4.3% vs. 9.2%, $p < 0.001$) compared to patients with LVEF reserve >0.^{39,41,44}

Nevertheless, the risk of cardiac events is an individual analysis that should consider all factors besides imaging information. Specific groups, such as the elderly and those with diabetes or known IHD, have a somewhat higher annual event rate (1.4-1.8%) despite normal MPI. The warranty period of a normal PET MPI in the setting of IHD is around two years, depending on risk factor control.⁴⁵

Several studies have also documented the greater prognostic value of PET-derived MFR compared to clinical factors and perfusion defect size and severity in patients with known or suspected IHD.^{46,47} The addition of MFR, as measured by PET, led to correct reclassification of estimated risk categories in 35% of patients with previously intermediate risk of death.⁴⁸ Although global MFR is only modestly associated with the overall extent and severity of angiographic disease,

both low MFR and severe angiographic disease were independently associated with adverse clinical events.⁴⁸ Global MFR is associated with major CV events independently of luminal angiographic severity and modifies the effect of coronary revascularization, underscoring the morbidity associated with diffuse atherosclerosis and microvascular disease.⁴⁹

Given that it indirectly reflects microvascular disease, MFR also has prognostic value in patients with diabetes and with chronic kidney disease.⁵⁰

The combination of these findings in prognostic assessment supports the conclusion that overall atherosclerotic disease burden and resultant macro- and microvascular ischemia, with or without obstructive epicardial lesions, are important contributors to overall CV risk. As such, PET-derived MFR may have particular prognostic importance as a sensitive global biomarker for functional IHD, especially in its ability to integrate complex pathophysiological sequelae at the target organ of interest.⁴⁹ Although the role of MFR in establishing prognosis is becoming clearer, more data are needed to generate sufficient evidence of its value.

Assessment of myocardial viability

There are numerous radiotracers that can measure cellular glucose metabolism either directly, such as FDG and ¹¹C-glucose, or indirectly, such as ¹¹C-palmitate and the various ¹⁸F-labeled fatty acid analogues.⁸ This discussion will focus on FDG.

Clinical setting and the role of glucose metabolism assessment

Three pathophysiological phenomena have been described in the setting of IHD in which myocardium is viable but dysfunctional: stunning, hibernation and remodeling.

Stunning is a state of transient regional contractile impairment, usually resulting from an ischemic insult, which persists for hours or weeks even after restoration of coronary flow (i.e. post-ischemic dysfunction). Recovery of myocardial function is spontaneous provided that myocardial perfusion remains normal.⁴³ The duration of stunning is directly proportional to the duration of the preceding ischemia.⁵¹

Hibernation refers to dysfunctional myocardium that is in a state of metabolic downregulation in response to chronic or repetitive ischemia. However, resting flow in hibernating myocardium may not be decreased to the extent that would account for the degree of cardiac dysfunction. In most cases, the impairment is only detected through reduced MFR, with reduced rest MBF only being seen in the most advanced cases. In this way, hibernation may represent a spectrum, with chronic repetitive stunning showing normal or near normal resting perfusion and impaired MFR at one end and reduced rest MBF at the other. Recovery of function in hibernating myocardium also requires coronary revascularization to restore adequate MFR.⁴³

Lastly, remodeling can occur, resulting in dysfunctional myocardium adjacent to the infarct or hibernation core that may or may not improve with revascularization, depending on improvement in other regions of the ventricle.⁵¹

In the setting of diminished, but not absent, regional MBF, reversible metabolic changes will occur, as an adaptive

measure to sustain myocardial viability. When MBF is absent, irreversible metabolic changes occur, followed by MI and cell death.⁸ Consequently, demonstration of preserved glucose metabolism by FDG is a marker of myocardial viability and the detection of viable myocardium is accurately estimated by referencing the level of myocardial glucose metabolism to the level of MBF.

Image interpretation and integration

Using a sequential perfusion-metabolism approach gives the most complete information, yielding different interpretation possibilities.

Normal perfusion images effectively guarantee myocardial viability, and therefore under conditions of normal perfusion it may not be necessary to continue with metabolic imaging. However, a pattern of normal perfusion coupled with reduced FDG uptake (so-called reversed perfusion-FDG mismatch) has been described in patients with left bundle branch block⁵² and also under conditions of repetitive myocardial stunning (e.g. early post-MI revascularization and in diabetic patients).^{43,53} This most likely reflects regions of jeopardized but viable myocardium, as the perfusion tracers reflect active metabolic trapping (Na⁺-K⁺-ATPase system for ⁸²Rb and ¹³N-ammonia).⁸

In regions of reduced MBF, an increase in myocardial metabolism by one or more grade therefore reflects a perfusion-metabolism mismatch, hence myocardial viability. By contrast, a regional reduction in FDG uptake in proportion to regional reduction in myocardial perfusion reflects the presence of a perfusion-metabolism match, hence myocardial scar or non-viable tissue.

Prognostic assessment and contribution to patient management

Observational evidence suggests that FDG PET, as a viability imaging tool, has the greatest sensitivity for predicting global LV functional recovery following revascularization, compared with SPECT, dobutamine stress echocardiography (DSE) and cardiac magnetic resonance imaging (MRI) ($p < 0.05$ vs. other modalities).⁵⁴⁻⁵⁶ Studies have consistently showed radionuclide techniques to be more sensitive for prediction of functional recovery, whereas techniques challenging contractile reserve such as cardiac MRI and DSE are more specific.⁵⁶

The degree of scarring on FDG PET has also been shown to be an important predictor of improvement in LVEF following revascularization. Beanland et al. found that the change in LVEF after revascularization was significantly greater in patients with less scar tissue (change of 9.0%, 3.7%, and 1.3% for small, moderate, or large scars, respectively).⁵⁷ Compared to scar, dysfunctional myocardium classified as hibernating or stunned by PET has a high chance of functional improvement following revascularization.⁵¹ There is evidence from multiple, predominantly retrospective, observational studies that the presence of hibernating myocardium involving as little as 5-7% of the left ventricle is associated with an outcome benefit from revascularization.^{58,59}

However, although there is a wealth of observational evidence showing the benefit of revascularization in terms of viability,⁵⁹⁻⁶¹ the subject remains controversial after the

primary results of the two largest prospective studies involving viability imaging, the Surgical Treatment for Ischemic Heart Failure (STICH) viability substudy⁶² and PET and Recovery Following Revascularization (PARR-2),⁶³ which did not yield clear and conclusive positive findings concerning an imaging-guided approach to revascularization.

The PARR-2 trial assessed whether the use of FDG PET in clinical decision-making leads to better clinical outcomes compared with standard care where FDG PET was not available. The study population included patients with LVEF $\leq 35\%$ who were being considered for revascularization, transplantation or heart failure work-up. The primary outcome was a composite of cardiac death, MI, or recurrent hospital stay for cardiac cause at one year. In the PET arm, the extent and severity of scar and mismatch were integrated with clinical parameters in a previously derived model for prediction of LV recovery after revascularization.⁶³ The trial did not demonstrate significant differences between the two groups. However, in a post-hoc analysis focusing on adherence to PET recommendation, there was a significant decrease in the hazard ratio for the primary outcome compared with standard care for revascularized patients with a mismatch of at least 7%.⁵⁸

In the viability substudy of the STICH trial, there was no relationship between myocardial viability and outcome benefit from revascularization.⁵¹ However, there are several limitations of this substudy that should be taken into consideration before drawing firm conclusions. PARR-2 and its substudies provided good evidence for using FDG PET to identify high-risk patients who may benefit from revascularization.^{58,63,64}

In spite of the above results, viability imaging appears to have a role as an adjunct to decision-making for complex patients (those with previous revascularization or multiple comorbidities), in whom both the risks and potential benefits of revascularization are highest.⁶⁵ At the same time, the STICH trial and its viability substudy, despite its limitations, have fueled the debate over the usefulness and appropriateness of viability imaging in patients with IHD and LV dysfunction. After the publication of this substudy the medical community eagerly awaits the results of the ongoing IMAGE-HF trial, which aims to address the role of cardiac imaging in management decisions and to ascertain which methods are most suitable according to different clinical scenarios.⁶⁶

Final remarks

The research and clinical community consider that individualizing therapy is essential in order to effectively improve patient outcomes. Cardiac imaging modalities are expected to play an important role in the assessment of the individual patient's pathological condition, helping to guide the treatment of cardiovascular disease.

Cardiac PET imaging is a powerful and accurate tool for the diagnosis of IHD. Compared to SPECT, it has a wider availability of perfusion tracers that can be adapted to different patients and situations, and involves lower radiation exposure. Its prognostic value is clearly established and it is already being used to guide clinical decisions. The addition of MBF quantification yields incremental diagnostic value and prognostic information, while solving some of the

interpretation issues associated with relative imaging methods such as SPECT and PET MPI. As it is able to identify various patient types, from those with risk factors and early diffuse IHD to those with advanced three-vessel disease, it can also be used to assess improvements following treatment such as lifestyle modification, exercise, optimal medical therapy and revascularization. Furthermore, MFR with PET is another sensitive tool that can reveal the presence of IHD and further improve risk stratification.

Several modalities are also now available for imaging viable myocardium, with FDG PET as the currently accepted gold standard. The concepts of hibernating, stunned and viable myocardium remain at the forefront of the debate regarding the appropriateness of revascularization for patients with IHD and significant LV dysfunction. In general, viability imaging may provide additional information for decision-making in complex patients in whom the potential risk of revascularization is greater.

There are many developments on the horizon for cardiac PET in the coming years, with new scanner technology as well as new radionuclides providing a myriad of potential applications for directly aiding patient management as well as improving understanding of multiple cardiac conditions. Although these developments are currently outpacing research that demonstrates their efficacy, it is reasonable to expect that cardiac PET will play an increasingly important role in the future.

PET imaging in its various forms will certainly help to establish a more direct relationship between an individual's diagnosis and therapy. Even so, improved standardization is needed and more research is required to determine its full impact on decisions that affect patient outcomes and resource use, and thus enable the full use of this valuable tool for diagnosis and risk stratification of patients with IHD, whatever their clinical scenario and stage of IHD. Although its clinical availability in Portugal is currently somewhat limited, the ever-increasing use of PET technology in cardiology and other fields, combined with advances in radiotracer technology, is expected to lead to an increasingly important role for cardiac PET imaging in the future.

Funding

This research received no specific grant from any funding agency in the public, commercial, or not-for-profit sectors.

Conflicts of interest

The authors have no conflicts of interest to declare.

References

- Montalescot G, Sechtem U, Achenbach S, et al. 2013 ESC guidelines on the management of stable coronary artery disease: the Task Force on the management of stable coronary artery disease of the European Society of Cardiology. *Eur Heart J*. 2013;34:2949–3003.
- Lewellen TK. Time-of-flight PET. *Semin Nucl Med*. 1998;28:268–75.
- Berman DS, Kang X, Slomka PJ, et al. Underestimation of extent of ischemia by gated SPECT myocardial perfusion imaging in patients with left main coronary artery disease. *J Nucl Cardiol*. 2007;14:521–8.
- Di Carli MF. Advances in positron emission tomography. *J Nucl Cardiol*. 2004;11:719–32.
- Bratis K, Mahmoud I, Chiribiri A, et al. Quantitative myocardial perfusion imaging by cardiovascular magnetic resonance and positron emission tomography. *J Nucl Cardiol*. 2013;20:71–3, 860–70; quiz 57–9.
- Juneau D, Erthal F, Ohira H, et al. Clinical PET myocardial perfusion imaging and flow quantification. *Cardiol Clin*. 2016;34:69–85.
- Wackers FJ, Soufer R, Zaret BL, et al. Nuclear Cardiology. In: Mann, Zipes, Libby Bonow, ed. *Braunwald's Heart Disease: a textbook of cardiovascular medicine*. Philadelphia, PA: Elsevier/Saunders. 2012:293–339.
- Dilsizian V, Bacharach SL, Beanlands RS, et al. ASNC imaging guidelines/SNMMI procedure standard for positron emission tomography (PET) nuclear cardiology procedures. *J Nucl Cardiol*. 2016;23:1187–226.
- Zamorano JLB, Knuuti J, Lancellotti P, et al. *The ESC Textbook of Cardiovascular Imaging second ed.*. Oxford University Press. 2015:258–70.
- Di Galleonardo V, Wilson DM, Keshari KR. The Potential of Metabolic Imaging. *Semin Nucl Med*. 2016;46:28–39.
- McArdle B, Dowsley TF, Cocker MS, et al. Cardiac PET: metabolic and functional imaging of the myocardium. *Semin Nucl Med*. 2013;43:434–48.
- Johnson PC. Autoregulation of blood flow. *Circ Res*. 1986;59:483–95.
- Jenni R, Kaufmann PA, Jiang Z, et al. In vitro validation of volumetric blood flow measurement using Doppler flow wire. *Ultrasound Med Biol*. 2000;26:1301–10.
- Jenni R, Matthews F, Aschkenasy SV, et al. A novel in vivo procedure for volumetric flow measurements. *Ultrasound Med Biol*. 2004;30:633–7.
- Ohira H, Dowsley T, Dwivedi G, et al. Quantification of myocardial blood flow using PET to improve the management of patients with stable ischemic coronary artery disease. *Future Cardiol*. 2014;10:611–31.
- Chareonthaitawee P, Kaufmann PA, Rimoldi O, et al. Heterogeneity of resting and hyperemic myocardial blood flow in healthy humans. *Cardiovasc Res*. 2001;50:151–61.
- Lortie M, Beanlands RS, Yoshinaga K, et al. Quantification of myocardial blood flow with ⁸²Rb dynamic PET imaging. *Eur J Nucl Med Mol Imaging*. 2007;34:1765–74.
- Ziadi MC. Myocardial flow reserve (MFR) with positron emission tomography (PET)/computed tomography (CT): clinical impact in diagnosis and prognosis. *Cardiovasc Diagn Ther*. 2017;7:206–18.
- Gould KL, Johnson NP, Bateman TM, et al. Anatomic versus physiologic assessment of coronary artery disease: Role of coronary flow reserve, fractional flow reserve, and positron emission tomography imaging in revascularization decision-making. *J Am Coll Cardiol*. 2013;62:1639–53.
- Kaufmann PA, Camici PG. Myocardial blood flow measurement by PET: technical aspects and clinical applications. *J Nucl Med*. 2005;46:75–88.
- Driessen RS, Raijmakers PG, Stuijzand WJ, et al. Myocardial perfusion imaging with PET. *Int J Cardiovasc Imaging*. 2017;33:1021–31.
- Danad I, Uusitalo V, Kero T, et al. Quantitative assessment of myocardial perfusion in the detection of significant coronary artery disease: cutoff values and diagnostic accuracy of quantitative [(15)O]H₂O PET imaging. *J Am Coll Cardiol*. 2014;64:1464–75.
- Majmudar MD, Murthy VL, Shah RV, et al. Quantification of coronary flow reserve in patients with ischaemic and non-ischaemic

- cardiomyopathy and its association with clinical outcomes. *Eur Heart J Cardiovasc Imaging*. 2015;16:900–9.
24. Jaarsma C, Leiner T, Bekkers SC, et al. Diagnostic performance of noninvasive myocardial perfusion imaging using single-photon emission computed tomography, cardiac magnetic resonance, and positron emission tomography imaging for the detection of obstructive coronary artery disease: a meta-analysis. *J Am Coll Cardiol*. 2012;59:1719–28.
 25. Mc Ardle BA, Dowsley TF, deKemp RA, et al. Does rubidium-82 PET have superior accuracy to SPECT perfusion imaging for the diagnosis of obstructive coronary disease? A systematic review and meta-analysis. *J Am Coll Cardiol*. 2012;60:1828–37.
 26. Schuijff JD, Poldermans D, Shaw LJ, et al. Diagnostic and prognostic value of non-invasive imaging in known or suspected coronary artery disease. *Eur J Nucl Med Mol Imaging*. 2006;33:93–104.
 27. Di Carli MF, Dorbala S, Meserve J, et al. Clinical myocardial perfusion PET/CT. *J Nucl Med*. 2007;48:783–93.
 28. Kaster T, Mylonas I, Renaud JM, et al. Accuracy of low-dose rubidium-82 myocardial perfusion imaging for detection of coronary artery disease using 3D PET and normal database interpretation. *J Nucl Cardiol*. 2012;19:1135–45.
 29. Nakazato R, Berman DS, Dey D, et al. Automated quantitative Rb-82 3D PET/CT myocardial perfusion imaging: normal limits and correlation with invasive coronary angiography. *J Nucl Cardiol*. 2012;19:265–76.
 30. Parker MW, Iskandar A, Limone B, et al. Diagnostic accuracy of cardiac positron emission tomography versus single photon emission computed tomography for coronary artery disease: a bivariate meta-analysis. *Circ Cardiovasc Imaging*. 2012;5:700–7.
 31. Danad I, Raijmakers PG, Driessen RS, et al. Comparison of Coronary CT Angiography, SPECT, PET, and Hybrid Imaging for Diagnosis of Ischemic Heart Disease Determined by Fractional Flow Reserve. *JAMA Cardiol*. 2017;2:1100–7.
 32. Yoshinaga K, Katoh C, Manabe O, et al. Incremental diagnostic value of regional myocardial blood flow quantification over relative perfusion imaging with generator-produced rubidium-82 PET. *Circ J*. 2011;75:2628–34.
 33. Hajjiri MM, Leavitt MB, Zheng H, et al. Comparison of positron emission tomography measurement of adenosine-stimulated absolute myocardial blood flow versus relative myocardial tracer content for physiological assessment of coronary artery stenosis severity and location. *JACC Cardiovasc Imaging*. 2009;2:751–8.
 34. Fiechter M, Ghadri JR, Gebhard C, et al. Diagnostic value of ¹³N-ammonia myocardial perfusion PET: added value of myocardial flow reserve. *J Nucl Med*. 2012;53:1230–4.
 35. Kajander SA, Joutsiniemi E, Saraste M, et al. Clinical value of absolute quantification of myocardial perfusion with (15)O-water in coronary artery disease. *Circ Cardiovasc Imaging*. 2011;4:678–84.
 36. Merhige ME, Breen WJ, Shelton V, et al. Impact of myocardial perfusion imaging with PET and (82)Rb on downstream invasive procedure utilization, costs, and outcomes in coronary disease management. *J Nucl Med*. 2007;48:1069–76.
 37. Dorbala S, Di Carli MF, Beanlands RS, et al. Prognostic value of stress myocardial perfusion positron emission tomography: results from a multicenter observational registry. *J Am Coll Cardiol*. 2013;61:176–84.
 38. Yoshinaga K, Chow BJ, Williams K, et al. What is the prognostic value of myocardial perfusion imaging using rubidium-82 positron emission tomography? *J Am Coll Cardiol*. 2006;48:1029–39.
 39. Dorbala S, Di Carli MF, Cardiac PET. perfusion: prognosis, risk stratification, and clinical management. *Semin Nucl Med*. 2014;44:344–57.
 40. Lertsburapa K, Ahlberg AW, Bateman TM, et al. Independent and incremental prognostic value of left ventricular ejection fraction determined by stress gated rubidium 82 PET imaging in patients with known or suspected coronary artery disease. *J Nucl Cardiol*. 2008;15:745–53.
 41. Dorbala S, Vangala D, Sampson U, et al. Value of vasodilator left ventricular ejection fraction reserve in evaluating the magnitude of myocardium at risk and the extent of angiographic coronary artery disease: a ⁸²Rb PET/CT study. *J Nucl Med*. 2007;48:349–58.
 42. Shaw LJ, Iskandrian AE. Prognostic value of gated myocardial perfusion SPECT. *J Nucl Cardiol*. 2004;11:171–85.
 43. Anagnostopoulos C, Georgakopoulos A, Pianou N, et al. Assessment of myocardial perfusion and viability by positron emission tomography. *Int J Cardiol*. 2013;167:1737–49.
 44. Dorbala S, Hachamovitch R, Curillova Z, et al. Incremental prognostic value of gated Rb-82 positron emission tomography myocardial perfusion imaging over clinical variables and rest LVEF. *JACC Cardiovasc Imaging*. 2009;2:846–54.
 45. Hachamovitch R, Hayes S, Friedman JD, et al. Determinants of risk and its temporal variation in patients with normal stress myocardial perfusion scans: what is the warranty period of a normal scan? *J Am Coll Cardiol*. 2003;41:1329–40.
 46. Murthy VL, Naya M, Foster CR, et al. Improved cardiac risk assessment with noninvasive measures of coronary flow reserve. *Circulation*. 2011;124:2215–24.
 47. Ziadi MC, Dekemp RA, Williams KA, et al. Impaired myocardial flow reserve on rubidium-82 positron emission tomography imaging predicts adverse outcomes in patients assessed for myocardial ischemia. *J Am Coll Cardiol*. 2011;58:740–8.
 48. Murthy VL, Lee BC, Sitek A, et al. Comparison and prognostic validation of multiple methods of quantification of myocardial blood flow with ⁸²Rb PET. *J Nucl Med*. 2014;55:1952–8.
 49. Taqueti VR, Di Carli MF. Radionuclide myocardial perfusion imaging for the evaluation of patients with known or suspected coronary artery disease in the era of multimodality cardiovascular imaging. *Prog Cardiovasc Dis*. 2015;57:644–53.
 50. Murthy VL, Naya M, Foster CR, et al. Association between coronary vascular dysfunction and cardiac mortality in patients with and without diabetes mellitus. *Circulation*. 2012;126:1858–68.
 51. Ohira H, Mc Ardle B, Cocker MS, et al. Current and future clinical applications of cardiac positron emission tomography. *Circ J*. 2013;77:836–48.
 52. Nowak B, Sinha AM, Schaefer WM, et al. Cardiac resynchronization therapy homogenizes myocardial glucose metabolism and perfusion in dilated cardiomyopathy and left bundle branch block. *J Am Coll Cardiol*. 2003;41:1523–8.
 53. Di Carli MF, Prcevski P, Singh TP, et al. Myocardial blood flow, function, and metabolism in repetitive stunning. *J Nucl Med*. 2000;41:1227–34.
 54. Schinkel AF, Bax JJ, Poldermans D, et al. Hibernating myocardium: diagnosis and patient outcomes. *Curr Probl Cardiol*. 2007;32:375–410.
 55. Underwood SR, Bax JJ, vom Dahl J, et al. Imaging techniques for the assessment of myocardial hibernation Report of a Study Group of the European Society of Cardiology. *Eur Heart J*. 2004;25:815–36.
 56. Schinkel AF, Bax JJ, Delgado V, et al. Clinical relevance of hibernating myocardium in ischemic left ventricular dysfunction. *Am J Med*. 2010;123:978–86.
 57. Beanlands RS, Ruddy TD, deKemp RA, et al. Positron emission tomography and recovery following revascularization (PARR-1): the importance of scar and the development of a prediction rule for the degree of recovery of left ventricular function. *J Am Coll Cardiol*. 2002;40:1735–43.
 58. D'Egidio G, Nichol G, Williams KA, et al. Increasing benefit from revascularization is associated with increasing amounts of

- myocardial hibernation: a substudy of the PARR-2 trial. *JACC Cardiovasc Imaging*. 2009;2:1060–8.
59. Di Carli MF, Davidson M, Little R, et al. Value of metabolic imaging with positron emission tomography for evaluating prognosis in patients with coronary artery disease and left ventricular dysfunction. *Am J Cardiol*. 1994;73:527–33.
 60. Di Carli MF, Asgarzadie F, Schelbert HR, et al. Quantitative relation between myocardial viability and improvement in heart failure symptoms after revascularization in patients with ischemic cardiomyopathy. *Circulation*. 1995;92:3436–44.
 61. Lee KS, Marwick TH, Cook SA, et al. Prognosis of patients with left ventricular dysfunction, with and without viable myocardium after myocardial infarction Relative efficacy of medical therapy and revascularization. *Circulation*. 1994;90:2687–94.
 62. Bonow RO, Maurer G, Lee KL, et al. Myocardial viability and survival in ischemic left ventricular dysfunction. *N Engl J Med*. 2011;364:1617–25.
 63. Beanlands RS, Nichol G, Huszti E, et al. F-18-fluorodeoxyglucose positron emission tomography imaging-assisted management of patients with severe left ventricular dysfunction and suspected coronary disease: a randomized, controlled trial (PARR-2). *J Am Coll Cardiol*. 2007;50:2002–12.
 64. Abraham A, Nichol G, Williams KA, et al. 18F-FDG PET imaging of myocardial viability in an experienced center with access to 18F-FDG and integration with clinical management teams: the Ottawa-FIVE substudy of the PARR 2 trial. *J Nucl Med*. 2010;51:567–74.
 65. Mielniczuk LM, Beanlands RS. Does imaging-guided selection of patients with ischemic heart failure for high risk revascularization improve identification of those with the highest clinical benefit?: Imaging-guided selection of patients with ischemic heart failure for high-risk revascularization improves identification of those with the highest clinical benefit. *Circ Cardiovasc Imaging*. 2012;5:262–70, discussion 270.
 66. O'Meara E, Mielniczuk LM, Wells GA, et al. Alternative Imaging Modalities in Ischemic Heart Failure (AIMI-HF) IMAGE HF Project I-A: study protocol for a randomized controlled trial. *Trials*. 2013;14:218.
 67. Schelbert HR. Quantification of myocardial blood flow: what is the clinical role? *Cardiol Clin*. 2009;27:277–89.
 68. Camici PG, Crea F. Coronary microvascular dysfunction. *N Engl J Med*. 2007;356:830–40.