



2013



DEPARTAMENTO DE CIÊNCIAS DA VIDA

FACULDADE DE CIÊNCIAS E TECNOLOGIA
UNIVERSIDADE DE COIMBRA

Perimortem Blunt Force Trauma Analysis

On the Reconstruction of the Circumstances of Death of
Human Skeletal Remains

Luísa Maria de Oliveira Marinho

2013



DEPARTAMENTO DE CIÊNCIAS DA VIDA

FACULDADE DE CIÊNCIAS E TECNOLOGIA
UNIVERSIDADE DE COIMBRA

Perimortem Blunt Force Trauma Analysis

On the Reconstruction of the Circumstances of Death of
Human Skeletal Remains

Dissertação apresentada à Universidade de Coimbra para cumprimento dos requisitos necessários à obtenção do grau de Mestre em Evolução e Biologia Humanas, realizada sob a orientação científica do Professor Doutor Hugo Cardoso (Simon Fraser University) e da Professora Doutora Ana Luísa Santos (Universidade de Coimbra)

Luísa Maria de Oliveira Marinho

2013

Table of Contents

List of Figures	iv
List of Tables	v
Abstract/Keywords	vi
Resumo/Palavras-chave	vii
Acknowledgements	viii

Chapter 1. Introduction

1.1. Trauma Analysis – Principles and Intents	2
1.1.1. Trauma Mechanism: Blunt Force, Sharp Force and Ballistic Trauma	2
1.1.2. Injuries Timing: The Perimortem Interval Problematic	3
1.2. Fractures	4
1.2.1. Classification Systems	4
1.2.2. Classification of Forces	5
1.2.3. Skeletal Fracture Patterns	6
1.3. Perimortem Trauma Analysis: Potentialities and Limitations	7
1.4. Research Goals	7

Chapter 2. Materials & Methods

2.1. The Study Sample	10
2.1.1. The Sampling Criteria	10
2.1.2. The Sample Profile	11
2.2. The Skeletal Data Collection and the Analytical Process	12
2.3. The Autopsy Reports Records	13

Chapter 3. Results & Discussion

3.1. Perimortem Blunt Force Trauma Analysis: The Skeletal Findings	15
3.2. The Circumstances of Death: Skeletal Findings <i>versus</i> Autopsy Reports	35

Chapter 4. Final Remarks	42
---------------------------------------	-----------

Appendices

A. Tables containing summarized information of each individual skeletal remains analysis of perimortem blunt force trauma evidence.

B. Table containing summarized information on the autopsy records of each individual analysed.

List of Figures

Chapter 1.

- 1.1.** Classification of Incomplete (on the left) and Complete (on the right) Fractures. 5
The arrows on the right (complete fractures) indicate the direction of force. This is the classification adopted by Alison Galloway (1999: 47, 50, 53).
- 1.2.** Schematic representation of forces acting upon bone and producing fracture. The 6
arrows indicate the direction of force. A – Tension; B – Compression; C – Rotation; D
– Bending; E – Shearing (adapted from Ortner, 2003: 120)

Chapter 3.

- 3.1.** Tripod fracture of the right zygomaticomaxillary complex (arrows point fracture 18
location).
- 3.2.** Incomplete transverse fracture (arrow) of the root of the zygomatic process of the 19
left temporal bone.
- 3.3. A)** Transverse fractures of the sternal body at the level of 3rd and 4th interspaces 20
(arrows), suggesting a blow directed posteriorly with impact over the middle third of
the body. **B)** Oblique fractures of the left ribs: shaft middle third of the 1st and 2nd,
and, shaft posterior third of the 3rd and 4th.
- 3.4.** Transverse fracture (arrow) of the diaphysis middle third of the left femur. 21
- 3.5.** Butterfly fractures of left ribs 5 to 7, with the presumable tensile site being located 23
on the inferior border of the posterior third of the shaft.
- 3.6.** Fracture of the anterior tibial eminence (arrow) by avulsion of the anterior cruciate 24
ligament and an incomplete wedge fracture (arrow) of the medial condyle of the left
tibia (superior view of the tibial plateau; anterior is up).
- 3.7. A)** Transverse (at the vertebral end) and oblique (at the middle third) fractures of 26
the 1st right rib. **B)** Incomplete vertical fracture of the right transverse process of the
1st thoracic vertebra (arrows point fractures location).
- 3.8.** Transverse odontoid and C2 body fracture (anterior view; arrow points fracture 27
location).
- 3.9.** Bilateral posterior arch fractures of C1 and C2 and bilateral laminar fracture of 28
two other lower cervical vertebrae.
- 3.10. A)** Linear fracture extending from the suprascapular notch (arrow) to the superior 31
and medial borders of the body of the left scapula. **B)** Left upper extremity:
supracondylar “H” fracture of the humerus, transverse fracture of the radial neck and
olecranon oblique fracture of the ulna. **C)** Fracture of the right radial styloid process

(inferior view, anterior is up). D) Oblique fracture of the distal third of the right ulna diaphysis.	
3.11. Body (A) and subcondylar (B) fractures on the left side of the mandible.	33
3.12. Distribution of the totality of circumstances of death, both proposed and reported.	36

List of Tables

Chapter 2.

2.1. Sample demographic profile including date of death range, age at death (yo- years old), and sex and age distribution.	11
---	----

Chapter 3.

3.1. Individual comparison of the circumstances of death proposed by the analysis of the skeletal remains with those reported on the autopsy records.	35
3. 2. Summarized features according to reported circumstances of death, namely, the minimum and maximum number (#) of injured body regions, and frequency (f) of each region being involved within the totality of cases allocated to each circumstance (N).	39

Abstract

The study of the mechanisms involved in the production of blunt force trauma in human skeletal remains has been one of the last key developments of the biological anthropology practice. The research on the biomechanics of blunt injuries, particularly those sustained around the time of death, plays a crucial role in the attempt to understand the circumstances of death. Despite the advances in new methodological techniques, the study of archaeological material hardly allows the corroboration of traumatic findings in the skeleton analysis. The purpose of this study is thus to evaluate the reliability of the reconstruction of the events surrounding death, through the analysis of perimortem blunt force trauma evidence in skeletal remains with available medicolegal data on the death circumstances. The sample consists of 22 individuals, 21 (7 females and 14 males) from the identified human skeletal collection housed at the National Museum of Natural History and Science, in Lisbon (Portugal), and one male individual from the collection of the Life Sciences Department of the University of Coimbra (Portugal), who died under violent circumstances and were submitted to medico-legal autopsy at the National Institute of Legal Medicine and Forensic Sciences, I.P. – Southern and Center Delegations, respectively. The human remains were observed at a macroscopic level without previous knowledge on the death circumstances. The characterization of the perimortem blunt force trauma findings followed several standard published criteria. In the last instance, hypotheses were raised to the most probable mechanisms/circumstances that may have produced the pattern of trauma observed in the individual. The results revealed agreement between the proposed and the reported circumstances of death for 13 individuals (59.1%), disagreement for 3 individuals (13.6%) and 3 cases of proposed and reported circumstances being similar. For three out of the 22 individuals (13.6%), the skeletal findings did not allow to put forth a probable circumstance of death. It was intended with this study to provide an important test to the applicability of the tools currently used for the “diagnostic” of the events leading to death. While in 59.1% of the cases the diagnostic was correct, this research draws attention to the difficulties and limitations encountered in determining a single circumstance of death from the study of skeletal remains. Trauma analysis thus demands further and continued research investment as plays a vital component that still carries a considerable amount of uncertainty, particularly inappropriate for forensic contexts.

Keywords Perimortem fractures; Blunt Force; Biomechanics; Injury Mechanisms; Death Circumstances

Resumo

O estudo dos mecanismos responsáveis pela produção de lesões traumáticas de natureza contundente constitui um dos desenvolvimentos chave na análise de restos humanos esqueletizados. A investigação da biomecânica associada à produção de lesões contundentes, particularmente as ocorridas próximo da altura da morte, é determinante para aceder às circunstâncias da morte do indivíduo. Apesar dos mais recentes desenvolvimentos metodológicos, o estabelecimento de uma relação inequívoca entre as lesões traumáticas observadas e os mecanismos subjacentes continua a ser problemática no estudo de material osteológico humano. A presente investigação visa a análise de lesões contundentes perimortem numa amostra osteológica humana com registo médico-legal acessível, com o intuito de averiguar a fiabilidade da reconstrução das circunstâncias da morte. A amostra seleccionada é composta por 22 indivíduos, 21 (7 do sexo feminino e 14 do sexo masculino) pertencentes à colecção de esqueletos identificados do Museu Nacional de História Natural e da Ciência, de Lisboa (Portugal), e um indivíduo do sexo masculino pertencente à colecção de esqueletos identificados do Departamento de Ciências da Vida da Universidade de Coimbra (Portugal), que terão morrido em circunstâncias violentas e sujeitos a exame de perícia médico-legal nas Delegações Centro e Sul do Instituto Nacional de Medicina Legal e Ciências Forenses, I.P. Os indivíduos em questão foram analisados macroscopicamente sem conhecimento prévio das circunstâncias da morte. A caracterização das lesões traumáticas contundentes ocorridas perimortem seguiu recomendações amplamente estandardizadas na literatura. Por fim, foram levantadas hipóteses mais prováveis quanto aos mecanismos e eventos que poderão ter estado na origem do padrão de trauma observado. Os resultados revelaram concordância entre as circunstâncias de morte propostas e as reportadas em 13 indivíduos (59.1%), discordância noutros três, e sobreposição de resultados em três outros casos. Para três dos 22 indivíduos analisados (13.6%), não foi possível inferir as circunstâncias de morte mais prováveis. Não obstante a obtenção de um diagnóstico correcto em mais de metade da amostra analisada, este estudo possibilitou salientar todo um conjunto de limitações associadas à determinação das circunstâncias de morte em vestígios esqueléticos humanos. Dada a pertinência do estudo de lesões traumáticas, urge a necessidade de se criarem e testarem métodos de análise mais efectivos de modo a colmatar as dificuldades de interpretação, particularmente em contexto forense, onde as hipóteses levantadas obrigam à existência uma base sustentável fiável.

Palavras-chave Fracturas perimortem, trauma contundente, biomecânica, mecanismos de lesão, circunstâncias de morte

Acknowledgments

I believe that patience is the keyword while expressing my gratitude to all that somehow contributed to this project.

First and foremost, I would like to thank my supervisors, Professor Hugo Cardoso and Professor Ana Luísa Santos for providing the opportunity to get me on the path of trauma analysis. Thank you for the excellent input, valuable comments and suggestions until the very end... and of course, for your patience!

At the National Museum of Natural History and Science, in Lisbon (Portugal), I would like to thank to Dr. Mafalda Madureira for the kind reception and assistance while collecting data.

At the Southern Delegation of the National Institute of Legal Medicine and Forensic Sciences, I.P., in Lisbon, I would like to thank Professor Jorge Costa Santos, for providing the access to the autopsy reports and to Dr. Manuela Marques, for the invaluable help with the data collection.

To my friends and co-workers, Sandra Assis and Alice Toso, I would like to particularly thank you for the patience and encouragement. I look forward to more laughs!

I also owe a huge thanks to my closest friends that, one way or another, gave me the strength to continue. There is no order while citing names, so thank you Tânia Carvalho, Joana Lucas, Ana Varela, Joana Almeida and Raquel Pinho. There are friendships that are worth to keep for a life time!

To my parents and sister I want to express my gratitude for all the support. Although not always understanding my choices, you have never said no.

I have to repeat myself and finish by mentioning you again. Hugo Cardoso, thank you for everything through the last years. You have been a wonderful inspiration and I feel so lucky for the invaluable support. It would not have been the same without your continuous encouragement.

CHAPTER 1

Introduction

1.1. Trauma Analysis – Principles and Intent

The skeletal trauma analysis has been part of the paleopathology discipline as an important testimony on the life difficulties of past populations, sex and social differences on types of injuries, quality of treatments, hygienic conditions and so on (e.g. Ortner, 2003). A relatively more recent evolution in forensic anthropology has promoted the development of the forensic trauma analysis field with new demands, new challenges and new goals (Dirkmaat et al., 2008).

The approaches to trauma analysis are quite variable as began to be the proposed definitions. Lovell (1997) states that trauma is widely perceived as an injury inflicted to living tissue by a force or mechanism extrinsic to the body. In its broadest sense, according to Ortner (2003) trauma may affect the skeleton in four different ways: (1) bone fracture, (2) joints dislocation, (3) compromising of the tissues' blood and nerve supply and (4) artificial alteration of the normal bone shape.

The causes of skeletal trauma include mechanical and non mechanical forces, being the result of accidental or intentional violence, therapeutic, cosmetic or cultural practices, or even of pathological conditions that increases the bone vulnerability to injury. The mechanical forces producing fracture and resulting in bone callus formation comprise the essence of paleopathological studies, being fractures generically the most frequent form of trauma within collections recovered from urban or rural cemeteries (Waldron, 2009).

1.1.1. Trauma Mechanism: Blunt Force, Sharp Force and Ballistic Trauma

Trauma mechanism is related to force or combination of forces that produce skeletal alterations and may be attained to ballistic trauma, sharp force and blunt force (Symes et al., 2012; Kroman and Symes, 2013). The guidelines published by the SWGANATH (2011) on trauma analysis presents a sub classification of trauma resulting from thermal exposure as an independent entity. According to this classification, sharp force trauma is probably the most studied field at present and may be produced by edged, pointed or beveled tools, as knives, saws or axes. The force is applied along a very narrow surface and is often combined with blunt force. Ballistic trauma is associated with high velocity projectile impact over small areas and gunshot wounds corresponds to the primarily cause of homicidal deaths (Dirkmaat et al., 2008). Blunt force trauma is produced by relatively low velocity impact over a relatively large blunt surface or object. This mechanism of trauma is probably the most complex and difficult to interpret “on the basis of skeletal characteristics alone” as stated by Dirkmaat et al. (2008) and will be the focus of the present study. Di Maio and Di Maio (2001) present abrasions,

contusions, lacerations and skeletal fractures within the blunt force injuries. They may result from direct or indirect contact being produced in assault cases by blows with feet, fists or blunt instruments or in situations of vehicle or sports accidents, or even being the result of falls and workplace accidents. The application of blunt force may cause bone breakage or, indirectly, bending, stretching and torsion of the skeleton (Galloway, 1999).

Trauma analysis guidelines proposed by the SWGANTH (2011) enumerates the following keys on the identification of blunt force trauma: presence of plastic deformation, delamination, fracture patterns of low velocity impact, identification of known clinical fractures (as parry or Colles fractures), fractures in contiguous or anatomically related bones, tool marks or impressions indicating impact sites, and beveling of fractures in the cranial vault indicating direction of force.

1.1.2. Injuries Timing: The Perimortem Interval Problematic

Determining the timing of a skeletal injury in relation to the time of death of the individual is an essential step on the analysis of trauma. For obvious reasons, this understanding becomes crucial in a forensic context, and relatively less relevant in a paleopathological scenario. However, the distinction between perimortem and antemortem can indirectly provide information on the treatments quality on a certain period, for instance (Ortner, 2003). On the other hand, even that a forensic anthropologist is not able to provide information on the cause of death through the analysis of complete skeletonized remains, he or she certainly plays an essential role on the reconstruction of the death circumstances. For that reason becomes vital to locate injuries in time in relation to the death event (Sauer, 1998; Cunha, 2006).

Attention should still be paid on the attempts of literally locate trauma into the periods “before death”, “at the time of death” and “after death” because “in skeletal tissue the divisions are based instead on qualities of the bone tissue” (Galloway, 1999). The most characteristic features of the “triple distinction” (Cunha, 2005/2006) are as follows: in antemortem trauma, evidences of bone healing, pseudoarthrosis, traumatic degenerative joint disease or surgical implants may be found; likewise, postmortem damage is determined by the absence of remodeling evidences, along with differential staining of surfaces and fracture characteristics of non plastic bone response; the perimortem interval may be considered a category where there is no evidence of osteogenic reaction, neither taphonomic alteration. The identification of perimortem trauma can be complex and problematic if typical features of plastic bone response and characteristic fracture patterns are not clearly identified. Therefore the approach to this problematic distinction and subsequent interpretations should incorporate a combination of knowledge on bone biomechanics and taphonomy, understanding the different patterns of flesh and dry bone responses to load (Ubelaker and Adams, 1995). Nevertheless, fractures occurring

shortly before death or soon after death may be difficult or even impossible to differentiate (Sauer, 1998; Moraitis and Spiliopoulou, 2006).

1.2. Fractures

The probability of occurrence, location and fracture pattern depends on a variety of factors including age and sex of the individual, the metabolic status, the integrity of adjacent soft tissue, the type and mechanism of injury and even the preexistence of any kind of condition that may affect bone or soft tissue (Resnick and Goergen, 2004).

In a broad sense, fracture refers to a complete or incomplete solution of continuity which affects the bone and/or cartilage, mostly caused by mechanical physical agents acting on a sudden and violent manner and thus exceeding skeletal natural tension or elasticity (Aufderheide and Rodríguez-Martín, 1998). To produce a fracture is then necessary that at least one of the following conditions is verified: isolated traumatic event, repeated stress or abnormal bone weakening (Rodríguez-Martín, 2006).

1.2.1. Classification Systems

Concerning to its classification, fractures can be organized following different systems and criteria that also vary according to different authors (e.g. Lovell, 1997; Aufderheide and Rodríguez-Martín, 1998; Ortner, 2003; Waldron, 2009). Serra (2001), from a clinical comprehensive point of view, suggests three fundamental keys to organize fracture terminology, distinguishing according to the cause, the compromise of soft tissue and according to the produced fracture lines.

Based on the entity causing fractures, those can be associated with traumatic events (direct violence, indirect violence or muscular traction), stress or even with a previous pathological condition (Dequeker et al., 1997; Ortner, 2003; Resnick e Goergen, 2004; Kumar et al., 2005).

According to the resultant soft tissue damage, fractures can be classified as closed (or simple) when adjacent tissue remains intact; open (or composed, following the old medical terminology) when the fracture communicates with the skin surface; or complicated when vital structures like arteries, nerves, joints or viscera are compromised. This type of distinction is not achievable from the analysis of dry bone alone.

Fractures may even be complete, incomplete, comminuted or compression fractures being determined by the fracture line produced (Serra, 2001). Galloway (1999) proposes a similar and extensive explanation based on the degree and pattern of breakage. A major division

is presented into complete or incomplete fracture including several different types within, as demonstrated in the two schemes in Figure 1.1.

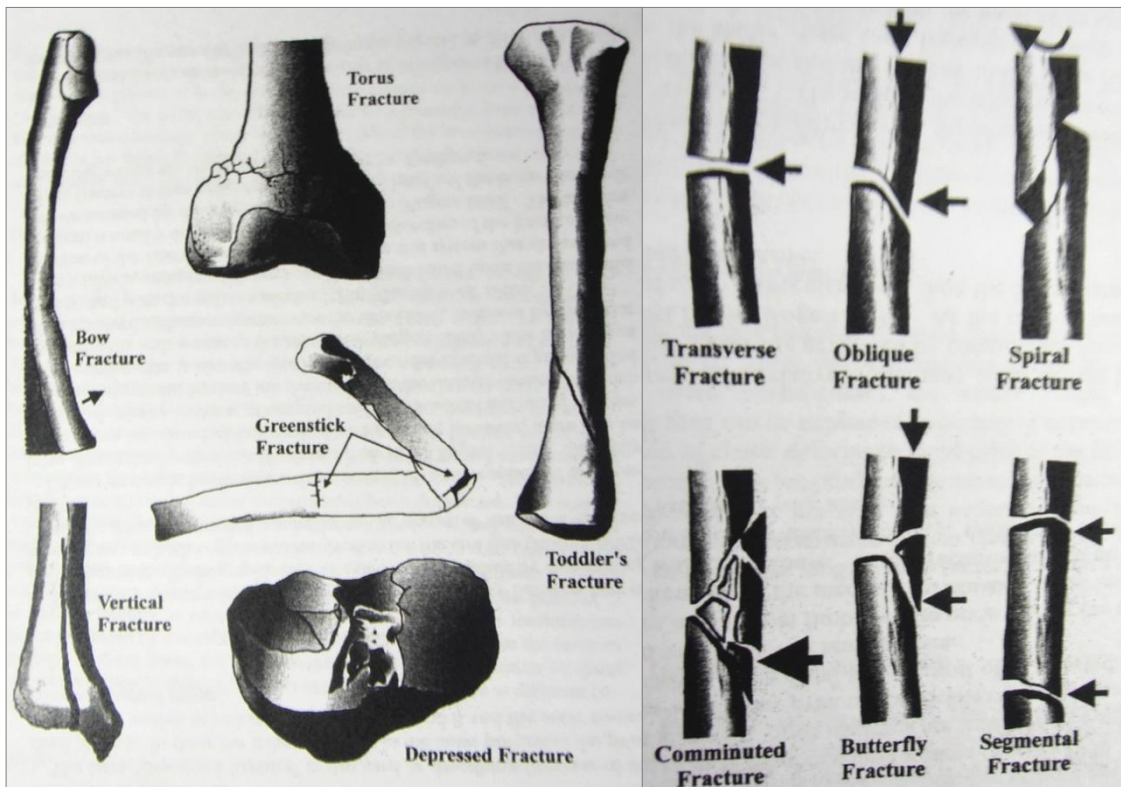


Figure 1.1. Classification of Incomplete (on the left) and Complete (on the right) Fractures. The arrows on the right (complete fractures) indicate the direction of force. This is the classification adopted by Alison Galloway (1999: 47, 50, 53).

1.2.2. Classification of Forces

Dynamic fractures are in fact the pathological condition most frequent in archaeological material and comprises the majority of the modern clinical practice (Ortner, 2003). Many fractures are the result of the direct or indirect application of more than one type of load acting upon bone.

There are then five basic types of loading that may be involved on bone blunt force damage as represented in Figure 1.2: tension (or stretching), compression (or compaction), torsion (or rotation/twisting), bending (angulation) and shearing (sliding) (e.g. Aufderheide and Rodríguez-Martín, 1998; Galloway, 1999; Ortner, 2003). Torsion, compression and bending forces are those that, acting isolated or combined, produce the majority of cases of skeletal damage (Resnick and Goergen, 2004).

The pattern of the produced fracture obviously depends on the interaction between the impacting object and the impacted area. But the problem begins with the variability of each bone reaction to load, the individual variation and the variation of each individual during life time, along with the frequent combination of different forces acting together. Even considering this inherent variability, general patterns may be identified and allows interpretation of the characteristics of the forces involved and corresponding injury events that produced the damage observed in the skeleton (Galloway, 1999; Resnick and Goergen, 2004).

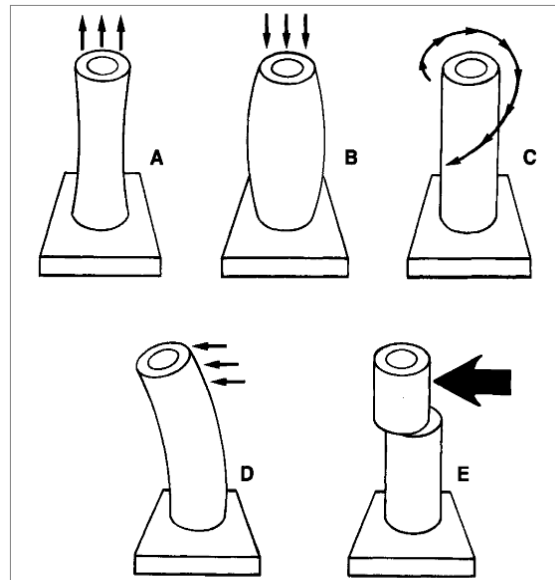


Figure 1.2. Schematic representation of forces acting upon bone and producing fracture. The arrows indicate the direction of force. A – Tension; B – Compression; C – Rotation; D – Bending; E – Shearing (adapted from Ortner, 2003: 120)

1.2.3. Skeletal Fracture Patterns

Every type of fracture in any anatomical location can be found while performing an anthropological study. However, there are differences in the fracture patterns produced, particularly by blunt force injury, according to the skeletal morphology becoming fundamental to determine its exact location and interpret the overall distribution. Several authors (e.g. Lovell, 1997; Ortner, 2003; Rodríguez-Martín, 2006) present different topographic division for the analysis of the traumatic findings on the human skeleton. Alison Galloway (1999), reporting specifically to blunt trauma analysis, structures as follows: the skull, including within it the cranial vault, facial bones, mandible and throat structures; the axial skeleton, referring to vertebrae, ribs and sternum analysis; the upper extremity, that includes clavicles, scapulae, humeri, forearm and hand bones; and the lower extremity, comprehending the hip bones, femora, patellae, tibiae, fibulae and foot bones.

1.3. Perimortem Trauma Analysis: Potentialities and Limitations

It is currently widespread among the scientific community the necessity for the establishment of standardized methodologies with specific steps to follow while analysing trauma in human skeletal remains, intending that way to maximize the quality and reproducibility of the results. Lovell (1997) points out that, despite the efforts made in the sense of analytical protocols standardization, researchers are not always familiar with the biomechanics underlying the production of traumatic injuries, critical to its understanding and interpretation.

Whilst describing and interpreting injuries, the type of fracture is the first feature to be recognized. This is followed by the identification of the mechanism that produced that damage, and in the end the interpretation of the injury ultimate cause (Lovell, 1997). Yet, this is far from being straightforward because one of the greatest problematic on trauma analysis is the huge variability in the expression of fractures. It is possible to observe great variations in fracture patterns produced by the same injury mechanism as well as there are similarities on the appearance of fractures resulting from different mechanisms.

Another subject under constant scrutiny is the intentionality of violence, attempting to understand solely from skeletal material analysis if trauma resulted from accidental or intentional violence. The same way, the reconstruction of the circumstances of death represents a demanding task often with several limitations. As expressed by Dirkmaat *et al.* (2008: página?), “the study of historic materials, with little room for corroboration of the proposed hypotheses, carried therefore a large weight of uncertainty and, at best, educated guessing, inappropriate for forensic contexts”.

There is another issue related to the evaluation of traumatic injuries that represents a major limitation to its interpretation and is related with the impossibility to analyse the human remains at the discovery scene. This should represent a critical part of a forensic investigation, but not doable while studying archaeological material.

1.4. Research Goals

The main purpose of this study is to evaluate the reliability of the reconstruction of the events surrounding death, through the analysis of perimortem blunt force trauma evidence on modern human skeletal remains, of known violent cause of death. Ultimately, the information contained in autopsy reports will be used to compare the actual circumstances of death with the events re-created from trauma analysis performed in the skeletal remains. It is so intended with

this study to answer the question: may the death circumstances be reliably reconstructed from trauma analysis? And further, to what extent?

The exceptional opportunity to establish a comparison between data obtained from perimortem trauma analysis of skeletal remains and the medicolegal data on the death circumstances will allow to understand and characterize the pattern of trauma associated to each circumstance and, at the same time, provide an important test to the applicability of tools currently used for the “diagnostic” of the events leading to death.

CHAPTER 2

***Materials &
Methods***

2.1. The Study Sample

The sample under study represents complete or fairly complete human skeletons of known identity, obtained from two Portuguese osteological reference series: the identified skeletal collections curated at the National Museum of Natural History and Science and at the Life Sciences Department at the University of Coimbra.

The identified skeletal collection housed at the National Museum of Natural History and Science, in Lisbon (Portugal) was amassed between 1981 and 1990 and is known as the Luís Lopes Collection or the “new Lisbon Collection” (Cardoso, 2000; 2006a; 2006b). Here it will be generally designated as the Lisbon Collection and the cases from this collection as NMNHS. The collection comprises now a total of 1.767 human skeletons (Cardoso, 2005; Cardoso, 2006a). Biographical data and the cause of death is known for the majority of the individuals, with the most common causes, as stated in Cardoso (2006a), being those related to problems of the circulatory system (33%). The variation sampled in the collection makes it of unpaired value, with almost equal proportion of males and females and with age at death ranging from birth to 98 years (Cardoso, 2000). The general conditions of conservation of the skeletons may vary but they are essentially complete (Cardoso, 2005; 2006a).

The Collection of Identified Skeletons of the Life Sciences Department of the University of Coimbra (earlier designated as “CEIMA”, but here now designated as “CEI-UC”) was accumulated between 1915 and 1942 (Fernandes, 1985). The Coimbra collection comprise a total of 505 individuals with an even sex distribution (266 males and 239 females), who died between 1904 and 1936 (Santos, 2000). The youngest individual in the Coimbra Collection is 7 years of age and the oldest died at 96 years of age. The information on the cause of death, available for the majority of the individuals, reveals high rates of causes related to both infections and circulatory system diseases (Curate, 2010).

2.1.1. The Sampling Criteria

The foremost criterion to proceed to the selection of the study sample relied on those individuals with a reported or suspected violent cause of death, where blunt force trauma is involved. The second selection moment settled on those individuals with available autopsy record data on the circumstances of death. The ultimate subset subjected to analysis excluded those cases with no identified evidences of perimortem skeletal trauma.

To reach the target sample, the individuals in the Lisbon Collection were firstly selected on the basis that their death was registered at the National Institute of Legal Medicine. These individuals would have been autopsied after death. As not all the individuals submitted to

medico-legal autopsy were registered at the National Institute of Legal Medicine, those with a death certificate from the 8th Civil Registration Office (*8^a. Conservatória do Registo Civil*) were also elected, as the National Institute of Legal Medicine, I.P. – Southern Delegation was on the area under its influence and some of the autopsy cases may have had the death recorded at this office. Out of those with known cause of death in the autopsy records, only those who died a violent death were selected, thus excluding individuals who died from natural causes, such as stroke or cardiac arrest. Causes of death mentioned as related to ballistic trauma were also excluded, as the purpose is to analyse blunt force injury patterns only. In the end, only 25 autopsy reports were available for access, further reducing the sample to only 21 individuals with signs of perimortem blunt force trauma to the skeleton and available autopsy records with known circumstances of death.

From the Coimbra Collection, only 6 individuals had available medico-legal information. From those, only one fulfilled the criteria of having both skeletal blunt force perimortem trauma evidences and known circumstance of death.

2.1.2. The Sample Profile

A total of 22 individuals (21 from the Lisbon collection and 1 from the Coimbra collection) were analysed. Biographical data such as name, sex, age at death, date of death, birthplace, occupation, filiation and address, are available in both collections and the cause of death is also known for all the individuals. The summary demographic profile of the total study sample is presented in Table 2.1. All the cases from the NMNHS correspond to accidental or suicidal deaths, while the case from the Coimbra collection was reported as a homicide.

Table 2.1. Sample demographic profile including date of death range, age at death (yo- years old), and sex and age distribution.

	Date of Death Range	Age at Death (yo)		Sex Distribution		Age Distribution	
		Range	Mean (\pm SD)	F (%)	M (%)	Non-adult (%)	Adult (%)
Lisbon Collection	1935-1974	8-82	44 (\pm 21)	7 (3.33%)	14 (66.7%)	3 (14.3%)	18 (85.7%)
Coimbra Collection	1926	21	-	-	1 (100%)	-	1 (100%)
TOTAL	1926-1974	8-82	43 (\pm 21)	7 (31.8%)	15 (68.2%)	3 (13.6%)	19 (86.4%)

2.2. The Skeletal Data Collection and the Analytical Process

The skeletal remains were observed at a macroscopic level, only with the aid of a low magnifying glass (10x). The documentation of the skeletal findings included descriptive text, diagrams and photographs. No destructive analysis was carried and the remains were examined without prior knowledge of the circumstances of death or of any information from the autopsy reports. A systematized protocol was followed for the study of each individual. An inventory of the human remains was the first step of the process, documented both through a Microsoft® Excel Worksheet and through a schematic representation of the presence of each bony and dental element. The conservation of each bone element was coded in a three stages scale (> 75%, 25-75%, <25%). General information including sex, age (adult or non-adult, if less than 18 years-old), and conservation and preservation conditions were also registered. If any potential autopsy artefacts were observed, as well as any observations on relevant taphonomic alterations or signs of antemortem trauma, they were also recorded in detail.

The perimortem nature of each blunt force trauma findings in the skeleton was possible to be ascertained by following standard published criteria (e.g. Galloway, 1999; Swganth, 2011). Here, consideration must be given as all the further discussed traumatic findings were all classified as being of a perimortem nature. The exact location of the bony lesions were documented, as well as a complete characterization including information about the dimensions, fracture angle, margins staining, fractured edges and beaveling. Once the lesions were identified, trauma analysis of each individual is presented according to the following studied variables: distribution of injuries by eight body regions* (neurocranium, viscerocranium, cervical spine, shoulder girdle, upper extremity, thoracic region, pelvis and lumbar spine, and lower extremity); specific bone fractured; laterality (left and right unilateral, or bilateral); type of fracture based on the degree and pattern of breakage** (incomplete, complete or any specific type of fracture pattern); probable point or points of impact for each lesion; classification of the force applied as relatively higher or lower energy trauma; probable direction of loading. The classification of type of fracture follows the one presented by Galloway (1999). Incomplete fractures include bow fracture or plastic deformation, torus or buckling fracture, greenstick fracture, vertical fracture and depressed fracture. Complete fractures are mainly divided into transverse, oblique, spiral, comminuted and epiphyseal. In the last instance, hypotheses are raised to the most probable mechanisms/circumstances that may have produced the general trauma pattern observed, according to relevant literature.

The classification of the events related to death was adapted from the International Statistical Classification of Diseases and Related Health Problems - 10th Revision (ICD-10), of

the World Health Organization. The features of this sample fall under the topic “External causes of morbidity and mortality”, not discriminating self-harm intentionality.

2.3. The Autopsy Reports Records

The autopsy reports from the individuals of the Lisbon collection were recovered from the archives of the National Institute of Legal Medicine and Forensic Sciences, I.P. – Southern Delegation. The medico-legal information of the individuals in the Coimbra collection had previously been transcribed by another investigator, in the late 1990’s, from the respective autopsy reports, held by the Center Delegation of the National Institute of Legal Medicine and Forensic Sciences, I.P.. The necessary confidentiality requirements were followed, ensuring that no element of identification of those involved in the process was published. The information contained and transcribed from the autopsy reports included biographic information (as sex, age, nativity, filiation), as well as information about the circumstances of death, provided by different sources, such as newspapers news, police statements, hospital records, or others. All the traumatic findings described in these sources, as well as any schemes from the external and internal examination of the body were collected, as were the final conclusions on the cause of death.

CHAPTER 3

***Results &
Discussion***

3.1. Perimortem Blunt Force Trauma Analysis: The Skeletal Findings

A total of 22 cases met the inclusion criteria for this study: one from the Coimbra identified skeletal collection (#1 CEI-UC) and 21 from the Lisbon collection (#1–#21 NMNHS). Tables summarizing the skeletal findings obtained from the analysis of perimortem blunt force trauma are presented in Appendix A. The description of those findings is detailed for each individual as follows. For each individual, the probable circumstances of death were determined from skeletal injury patterns and from reconstructing possible mechanisms behind their production.

Case #1 CEI-UC

This is a 21-years-old male individual whose skeletal remains were well preserved and conserved, except for C1, C2 and C6 which were not present. Perimortem fractures were found in two regions, the neurocranium and the thorax. A linear fracture was observed on the left parietal and sphenoid bones which probably resulted from direct bending force acting upon the bones from left to right and with the point of impact proximal to the left sphenoparietal suture. Oblique fractures were found on the anterior third of left ribs 2 and 4 and sternal end of left rib 11, being likely produced by a combination of compressive and bending forces which may be associated to lateral compaction on the left side of the torso, as a result of a number of different circumstances (Galloway, 1999). Also the presumable location of the direct impact on the skull (around the so-called hat brim line) makes it difficult to discriminate a direct blow to the head with an object (in this case of small to medium dimensions) from a fall (Kremer et al., 2008; Kremer and Sauvageau, 2009; Guyomarc'h et al., 2010). The analysis of these remains then suggests a fall from low height and/or direct blow to the head with an object as the most likely circumstances to have produced the observed trauma pattern.

Case #1 NMNHS

In this case, an adult male individual (40 years-old) was studied and his skeletal remains were considered well conserved and reasonably preserved. Only four cervical vertebrae were present with the axis being poorly preserved. In addition both pubic rami were fragmented. Evidences of perimortem blunt force trauma were limited to the cervical spine. Three out of the four cervical vertebrae were fractured. Atlas was fractured transversely and unilaterally on the right posterior arch. Both C7 and the other unidentified lower cervical vertebra presented

transverse fractures on the right lamina and left superior articular facet. Although the axis was poorly preserved, the presence of concurrent fractures of C2 is a valid assumption. Indirect trauma through mechanisms of hyperextension, hyperflexion and rotation are the most common causes of cervical spine injury and their isolated occurrence or, most likely, the combination of different forces is frequently associated to motor vehicle accidents and falls (Shkrum, 1989; Galloway, 1999). Blows to the vertex of the head are also a possible cause, but the absence of cranial or other fractures makes motor vehicle accident or fall (these usually associated with more abrupt forces) the most likely circumstances in this case.

Case #2 NMNHS

The skeletal remains of this adult male individual (51 years-old) were analysed and found to be generally poorly preserved and reasonably conserved. First and fourth cervical vertebrae, and second and third lumbar vertebrae were not present, as well as left clavicle and right pubic ramus. Trauma was limited to the cranium (neurocranium and viscerocranium) and ribs. A linear fracture – the result of compression and tension forces – extended from the left parietal bone (probable point of direct impact), longitudinally through the petrous portion of the left temporal bone. The petrous portion represents an area of greater bone thickness, associated with a higher loading force required to induce fracturing (Berryman and Symes, 1998; Swartz and Curtin, 2003). The same linear fracture also travelled into both the ethmoid and the right palatine bones. Despite poor preservation of the ribs, transverse fractures on the vertebral ends of the second and third left ribs were identified. This location most likely indicates that the force was directed anteriorly, with compaction and breakage point occurring near the spine (Daegling et al., 2008). The upper ribs, particularly the first and second ribs, are more protected due to their anatomical positioning making injuries to them being associated with more violent and extensive damage (Di Maio and Di Maio, 2001). In this case, a fall on the back from a high height, with a direct impact on both the cranium and the thoracic region would probably produce the observed pattern.

Case #3 NMNHS

The skeletal remains of this individual (female, 55 years-old) were poorly conserved and preserved. Several cranial bones were missing, along with the left scapula, the clavicle and the humerus, both pubic rami, and several of the vertebrae. Evidence of perimortem trauma was found in four regions of the skeleton namely the thorax, pelvis and lumbar spine, and upper and lower extremities. A transverse fracture was found on the middle third of the sternal body which suggests a blow directed posteriorly which impacted the lower third of the body (with this

portion being pushed posteriorly). Also, fractures were found on the vertebral ends of multiple ribs, on the left side, from upper (first three included) to lower ones, suggesting that the load was most likely sustained along the spine and anteriorly directed. A fracture with perimortem characteristics was found on the transition of middle to distal third of the left ulna diaphysis. The absence of the proximal fragment of the ulna makes it difficult to distinguish between an oblique and a butterfly fracture pattern, since fracture line behaviour cannot be determined when there are missing fragments. The location of this injury is more frequently associated with direct impacts (Lovell, 1997). Comminuted fractures were observed on sacrum and left hip bone. Both transverse and vertical fractures were observed on the upper segment of the sacrum, including one anteriorly located on the body of the first sacral vertebra and, posteriorly, on both articular facets. Moreover, the left hip bone was multi-fragmented presenting, according to its location, an iliac wing fracture, an acetabular fracture and both pubic and ischial ramus fractures (Letournel, 1980). Understanding the type and direction of multiple forces from different angles acting upon this particular bone is a complex task, and considering the multiple defects found here, a series of injuries causing them should be assumed. The fracture found on the right tibia was produced by direct impact on the transition of middle to proximal third of the diaphysis, yet the comminuted pattern produced (high load associated) makes it difficult to understand the direction of applied force. A spiral fracture was observed on the distal third of the left fibula with the fracture line beginning posterior and running anteriorly and proximally. This type of injury is usually produced by indirect trauma to the ankle, which can be the result of combination of pronation and rotation of the ankle, fracturing the fibula above the level of the syndesmosis (Miller and Herbst, 2005; Teresinski, 2005). Although the distal epiphysis of the left tibia is poorly preserved it is reasonable to also assume a fracture of the medial malleolus as part of the complex ankle fractures. The extensive damage observed on the sacrum and left hip bone, as well as the comminuted fracture of the right tibia were produced by sudden and high load impact acting upon those regions most likely as a result of a vehicle-pedestrian accident.

Case #4 NMNHS

The skeletal remains of this adult male individual (63 years-old) were well preserved and conserved. The skeleton revealed unilateral injuries with only the right zygomatic, right maxilla and bones of the right leg presenting perimortem fractures. A pattern of breakage with fracturing of the zygomatic arch, fracturing near the zygomaticofrontal suture and a fracture medial to the zygomaticomaxillary suture (Figure 3.1) forms the typical tripod fragment (Galloway, 1999). This usually results from a blow over the malar eminence (anterior-posteriorly and/or right to left directed). A butterfly fracture on the middle-diaphysis of the right tibia suggests a direct impact anterior-posteriorly directed, with forces of tension acting on the

posterior side and bending forces on the anterior one. Ipsilateral associated spiral fibular shaft fracture was found slightly more proximally than the tibial one. This type of injuries on the leg is common in pedestrians hit by motor vehicles (Galloway and Zephro, 2005) making the tripod fracture a possible consequence of a subsequent fall.

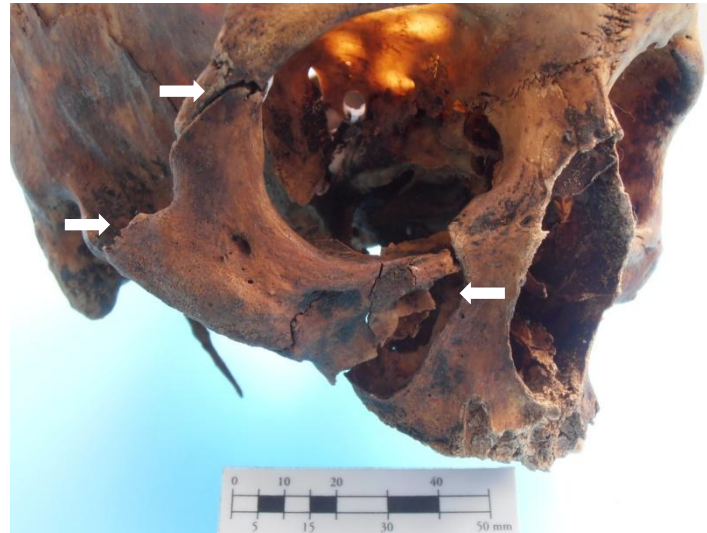

Figure 3.1. Tripod fracture of the right zygomaticomaxillary complex (arrows point fracture location).

Case #5 NMNHS

This skeleton belonging to a 33 year-old male was in a good state of preservation and conservation, except for the left hip bone which was not present. The neurocranium and viscerocranium were the only affected regions. A horizontal incomplete fracture was found on the root of the zygomatic process of the left temporal bone (Figure 3.2). The left zygomatic arch was transversely fractured in two distinct points with loss of a fragment in between. Bending forces acting directly over the zygomatic arch usually breaks it in three points (at each end of the arch and at point of impact), which is compatible with the morphology observed. However, the incomplete fracture of the zygomatic process would be more probably related to a direct impact over the zygomatic bone with anterior-posterior direction, which would also cause fracture of the zygomatic arch and the typical “3-legged” fracture pattern observed on the left zygomaticomaxillary complex (Galloway, 1999). Considering the absence of injuries on other regions of the skeleton, a single blow or an impact as result of a fall from a low height, to the left malar eminence seem the most plausible scenarios for this pattern of lesions.



Figure 3.2. Incomplete transverse fracture (arrow) of the root of the zygomatic process of the left temporal bone.

Case #6 NMNHS

This is a case of a 38 year-old male, whose skeletal remains were generally well preserved (except for the vertebrae) and conserved (except for the right first rib which was absent). The analysis revealed perimortem injuries on the cervical spine, thorax and upper extremity. Although the vertebrae were poorly preserved, a fracture of the left posterior arch of C7 and a left lateral mass fracture of another unidentified cervical vertebra were observed. Also T4 revealed a vertical fracture on the right superior articular facet, with a sagittally oriented line. Interpreting vertebral injuries is always a complex task as they are usually the result of indirect trauma and more than one type of loading force. In this case, rotational forces possibly associated with flexion appear in the literature as the most plausible mechanisms (Galloway, 1999). Two transverse fractures were observed on the sternum body, the superior one between the 3rd and 4th costal notch, and the inferior between 4th and 5th costal notch (Figure 3.3 A). The fragment produced in between these two fracture lines seems to have been pushed posteriorly. Sternum fractures are usually produced by severe anterior-posterior compression or high load direct impact upon the sternum body (Di Maio and Di Maio, 2001). Also, cardiopulmonary resuscitation (CPR) manual technique sometimes produces fractures at the same level of 3rd or 4th interspace (Hoke and Chamberlain, 2004). Anterior rib fractures are also reported in association with manual CPR use, whilst posterior fractures are unlikely to occur (Pinto et al., 2013). In this case, trauma to the rib cage was found on the posterior third of the shaft in right ribs 2 to 5 (oblique morphology); on the anterior third of the 4th right rib; on the left side, oblique fractures of the first and second ribs were present on the lateral third; and, on the posterior third of the left 3rd and 4th ribs (Figure 3.3 B). The prevalence of a posterior location of the fractures and the involvement of the superior ribs on both sides (except for the

right first rib which was not conserved) make it most likely related to a high energy impact on the back toward the front. The involvement of the upper extremity in the trauma pattern of this individual is restricted to left radius and right fifth metacarpal. It is worth mentioning that both the distal epiphysis of both ulna were poorly preserved did not allow a proper trauma analysis. The longitudinal fracture of the fifth metacarpal (head and distal shaft) was most likely produced by direct blow or crushing, involving compression/tension forces (Galloway, 1999). The left radius exhibited a transverse and a spiral fracture on the distal third of the diaphysis. The transverse fracture, located about 1 cm above the articular surface for carpal bones, was produced by bending forces acting on the distal radius. Associated torsional forces acted upon this bone since a spiral fracture was produced just above the transverse one. A direct impact (as occurring during a fall) into the distal radius usually produces these types of injuries (Galloway, 1999). Consideration of the trauma observed points to a fall from a high height as the probable scenario.



Figure 3.3. A) Transverse fractures of the sternal body at the level of 3rd and 4th interspaces (arrows), suggesting a blow directed posteriorly with impact over the middle third of the body. **B)** Oblique fractures of the left ribs: shaft middle third of the 1st and 2nd, and, shaft posterior third of the 3rd and 4th.

Case #7 NMNHS

This is the case of a young 10 year-old male, whose skeletal remains were badly preserved and conserved. Several skeletal elements were missing including the scapulae and both clavicles, the sternum body, both pubic rami, both ulnae and the left radius. Only three bones, occipital, right parietal and left femur, exhibited signs of trauma. A linear fracture affecting both the parietal and the occipital bones was found on the right side. On the parietal bone the fracture line was only visible on the inner table above the right portion of the lambdoid

suture. The fracture line (visible both on the inner and outer tables) crossed the occipital bone vertically from the right lambdoid suture to the right occipital condyle. This fracture was most certainly produced by bending force acting directly on the occipital bone (posterior-anteriorly directed). A transverse fracture (Figure 3.4) was present on the middle diaphysis of the left femur (direction undetermined). This type of injury is common among children as a result of bending forces in vehicle-pedestrian accidents and falls (Galloway, 1999). The direct impact received on the occipital bone may have been the result of a fall subsequent to being hit on the left femur by a vehicle, or both could have been produced by a fall from a high height.

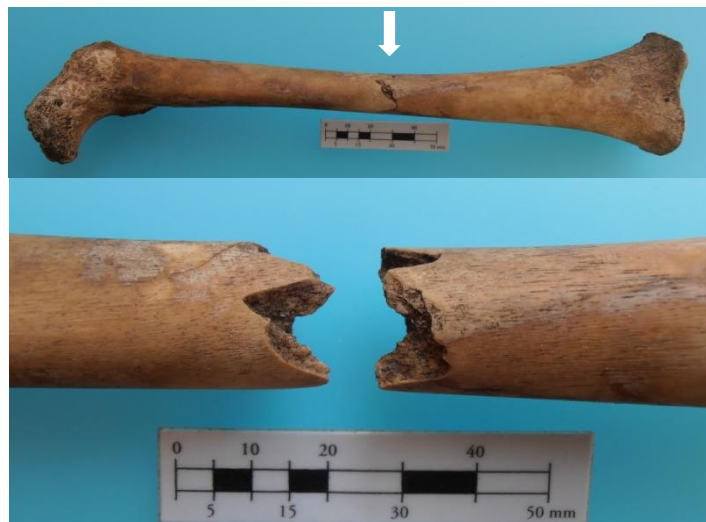

Figure 3.4. Transverse fracture (arrow) of the diaphysis middle third of the left femur.

Case #8 NMNHS

This is another case of a sub-adult male (9 years-old). While fairly complete (only nasal bones and some epiphysis were the major elements missing), the skeletal were also in good state of preservation. The cranium and one right rib were the only skeletal elements exhibiting fractures. Considerable perimortem damage was observed on the cranium, where almost every bone was involved. The complex pattern observed suggests a violent impact on the lateral-anterior right frontal bone (left-posteriorly directed). The frontal bone presents several linear fractures with loss of bone fragments, most certainly corresponding to the impact site. The two major fracture lines run from the front to the contralateral back, crossing over from the sella turcica to the foramen magnum and then from the front reaching the left temporal bone. At that point, the propagation of force originated a probable diastatic fracture on the lambdoid and occipitomastoid sutures. The petrous portion of the left temporal bone also shows a longitudinal fracture, anteriorly extralabyrinthine (classification according to Swartz and Curtin, 2003). Although complete bisecting of the base of the skull did not occur, the pattern resembles closely

the Type II of Hinge fractures described by Di Maio and Di Maio (2001). Other associated smaller diastatic and linear fractures were also found on the viscerocranium with involvement of the maxilla, the ethmoid and the left palatine. Besides the cranium, an incomplete transverse fracture was found on the transition of the middle to the posterior third of the shaft of the sixth right rib. The presumed tensile site was located on the visceral side and the fracture lines travelled to the dorsal surface in an oblique direction. A greenstick fracture was also observed on the vertebral end of the same rib. The mechanisms involved in the production of rib trauma are complicated by the curved structure of a rib and considering its anatomical context as part of the rib cage. In this case, both direct impact and anterior compression forces may have produced this single fracture. Nevertheless, incomplete fractures are suggested to be the result of a slow loading, low energy force (Love and Symes, 2004). In view of the skeletal injuries observed two scenarios can be put forth: either a direct blow with an object of considerable dimensions to the frontal bone with a subsequent fall that would explain rib fracturing, or a fall from high height landing primarily on the frontal bone.

Case #9 NMNHS

This is the case of a poorly preserved skeleton of a 43 year-old male. Being reasonably conserved (three cervical vertebrae, left clavicle, sternum body and pubic rami absent), only perimortem rib fractures were identified. On the right side, ribs six to eight show oblique fractures on the posterior third portion of the shaft. Injuries on this location are normally produced by impact along the spine from behind toward the front, although careful interpretations must be made (Galloway, 1999). Nevertheless, its isolated occurrence makes it impossible to reconstruct the most likely death circumstance, as a wide range of possible scenarios involve rib fractures.

Case #10 NMNHS

The skeletal remains of this 40 year-old adult male were analysed and considered to be in a good state of preservation and reasonably complete, noting that almost all facial bones were absent or fragmented and both the first ribs and the axis were not present. In this case almost all body regions were involved although the majority of injuries sustained were concentrated on the upper body. Skull, ribs from both sides, right radius and the right fibula were the elements exhibiting fractures. Although facial bones were poorly conserved, a high force impact with a large surface on the left side of the face is suggested by the following lesions: a vertical fracture of the mandible body (slightly left to the midline), a vertical fracture of the maxilla on the same parasagittal plane as that of the mandibular, comminuted fracturing of the sphenoid bone,

multiple linear fractures in the frontal bone (running posteriorly), and a transverse fracture on the root of the zygomatic process of the left temporal bone. Also, multiple rib fractures were concentrated on the vertebral ends on the right side, and on the posterior third of the shaft, on the left side. Oblique fractures were registered on the vertebral ends of ribs 2 to 6 and 8 and 9 on the right side. Also on the right side, ribs 7 and 10 presented greenstick fractures at the posterior third of the shaft. On the left side, butterfly morphology was observed on ribs 5 to 7, with the presumable tensile site being located on the inferior border of the posterior third of the shaft (Figure 3.5). The pattern is compatible with a direct high energy load acting on the back and anteriorly directed. The fracture on the right radius was the only injury in the upper extremities, exhibiting a butterfly fracture on the middle to proximal third of diaphysis. Its morphology suggests a direct impact on the medial surface, therefore implicating the prone position of the forearm while impacted. In the lower extremities, only an oblique fracture at the proximal epiphysis of the right fibula was found. The isolated occurrence of head or neck fractures of the fibula is not common, yet tends to be the result of direct blows (Galloway, 1999). The pattern of injuries observed in this case is not typically or straightforwardly assigned to one or more specific circumstances, particularly due to the concurrent anterior damage to the facial and cranial bones and simultaneously extensive damage to the rib cage concentrated on the posterior of the thorax, while the no extensive lesion are registered on the lower extremities. In this case, the most likely scenario will not be proposed, although high energy direct impacts are assumed.



Figure 3.5. Butterfly fractures of left ribs 5 to 7, with the presumable tensile site being located on the inferior border of the posterior third of the shaft.

Case #11 NMNHS

These skeletal remains belonging to a 27 year-old male were well preserved and conserved. Evidence of perimortem trauma was found unilaterally on the left sided and concentrated on the sacrum, the hip bone and leg bones. Besides those lesions, a single oblique

fracture was found on the lateral third of the shaft of the left eighth rib. Trauma located on the lateral curvature of ribs is usually associated with anterior-posterior compression of the chest wall. A lateral mass fracture of the left ala of the sacrum and acetabular t-shaped fracture and pubis symphysis separation (classification according to Letournel, 1980) on the left hip bone were also identified. Though always difficult to interpret multiple trauma to the pelvic “anatomical complex”, the pattern observed suggest a high load and sudden lateral impact (left to right oriented), probably through the left great trochanter (Fakler et al., 2007). On the left leg, both bones were injured. Both the proximal and the distal tibial epiphysis revealed signs of trauma. On the tibial plateau, a fracture of the anterior tibial eminence (by avulsion of the anterior cruciate ligament) and an incomplete wedge fracture of the medial condyle were observed (Figure 3.6). This type of injury usually involves rotation combined with varus and axial forces (Teresinski, 2005). The medial malleolus was also horizontally fractured through its base, which is usually related to pronation-abduction mechanisms (Teresinski, 2005), which also explains the oblique fracture observed on the diaphysis’ distal third of the ipsilateral fibula. Globally, the pattern of lesions seems compatible with a vehicle-pedestrian accident with the major impact being on the left side of the body at the level of the great trochanter.



Figure 3.6. Fracture of the anterior tibial eminence (arrow) by avulsion of the anterior cruciate ligament and an incomplete wedge fracture (arrow) of the medial condyle of the left tibia (superior view of the tibial plateau; anterior is up).

Case #12 NMNHS

The skeletal remains of this 40 year-old female were poorly preserved and conserved, particularly the rib cage. The sternum, the cervical spine, the proximal epiphyses of right radius and ulna were not present. This skeleton showed perimortem trauma on the upper (right

humerus) and lower extremities (both legs) and ribs in both sides. Only in four right sided ribs (3-6) it was possible to identify oblique fractures at the posterior third of the shaft. These were possibly produced by a direct impact from behind (posterior-anteriorly directed). Trauma to the right humerus consisted of a transverse fracture on the proximal third of diaphysis. This morphology indicates a considerable high energy load transmitted perpendicularly to the long axis of the bone producing severe angulation (Galloway, 1999). The fracture outline does not allow determination of direction of force. Thighs were not injured but bones of both legs were fractured. Both tibiae presented transverse (right) and oblique (left) fractures on the diaphysis' proximal third. The right fibula was injured at two different levels, showing a transverse fracture at the same level of the right tibia fractured, and another butterfly fracture at the diaphysis' middle third. Left fibula only exhibited a transverse fracture at the proximal epiphysis. Trauma to the legs was most certainly produced by a sudden and high energy direct impact with possible force direction from right to left. The all pattern of breakage, particularly the involvement of the two legs is often associated with vehicle-pedestrian accident.

Case #13 NMNHS

In this case of a male of advanced age (63 years-old), the skeletal remains were fairly complete and in a reasonably state of preservation. The right pubic ramus and the distal epiphyses of both radii were not present. Trauma was limited to the upper body, including the cranium, thorax and right humerus. A linear fracture was visible on the frontal bone near the right zygomaticofrontal suture, which appeared to run backward and from right to left, crossing the sella turcica (producing comminution of the sphenoid) and reaching the temporal bone (longitudinally sectioning the left petrous portion). The right zygomatic bone and maxilla also showed evidence of fracturing resulting in the so called tripod fragment. A single direct impact to the right malar eminence and frontal bone could have produced the observed pattern. In the thoracic region, the first right rib was fractured at two points (Figure 3.7 A): vertebral end (transverse) and middle third (oblique). In the thoracic spine, T1 also showed a vertical incomplete fracture on the right transverse process (Figure 3.7 B). This is likely to be related to the mentioned fractures of the first right rib, which were most probably produced by a direct impact over the rib cage, although its isolated occurrence does not allow for a clear understanding of probable force direction. The right humerus was the only other bone injured in this individual. Although fragmentation of the proximal portion of the diaphysis and epiphysis of the humerus was observed, the initial fracture line appears to be of an oblique nature, with probable impact occurring at the transition of the middle to the proximal third of the diaphysis (possibly right to left directed). Considering skull, thoracic and right humerus trauma, a fall

from a high height landing on the right side of the upper body is a plausible scenario to explain the injuries of this individual.



Figure 3.7. A) Transverse (at the vertebral end) and oblique (at the middle third) fractures of the 1st right rib. B) Incomplete vertical fracture of the right transverse process of the 1st thoracic vertebra (arrows point fractures location).

Case #14 NMNHS

This is the case of an 82 year-old female, whose skeletal remains were reasonably preserved and fairly complete, except for the right radius and ulna (only a proximal fragment of this was conserved). Two body regions were injured, with the neurocranium and axis exhibiting fractures. A linear fracture seems to run from the frontal bone down right through the sphenoid and temporal bones till it reaches right occipital condyle, but not completely sectioning it. The second cervical vertebra (Figure 3.8) presents a transverse odontoid and C2 body fracture (according to the classification system of fractures of the odontoid of Anderson and D'Alonzo, 1974). While trauma to the neurocranium was most likely produced by a direct impact to the right side of the frontal bone (right to left and anterior-posteriorly directed), fracture of the axis was the result of indirect forces applied to the cervical spine. Both sudden hyperflexion and hyperextension may result in odontoid injuries as are seen in motor vehicle accidents and falls from height (Shkrum et al., 1989). In this case, and considering the lack of other skeletal elements injured, a motor vehicle accident emerges as the most likely circumstance of death.



Figure 3.8. Transverse odontoid and C2 body fracture (anterior view; arrow points fracture location).

Case #15 NMNHS

The skeleton of a 52 year-old male was analysed. Although globally well preserved and fairly complete, the skeletal remains were lacking four cervical vertebrae, and both ischiopubic rami. Evidences of perimortem trauma were found in five bones: the first, second and two other unidentified cervical vertebrae, and first thoracic vertebra. Both the atlas and the axis (Figure 3.9) revealed bilateral posterior arch fracture, through the neural arch, which is according to the literature commonly caused (indirectly) by hyperextension induced to the cervical spine, forcing posterior arches against each other and to the occipital bone (Galloway, 1999). The other two cervical vertebrae had bilateral laminar fractures (Figure 3.9) which are also associated to hyperextension of the lower neck that causes compression of the posterior processes against each others. A left pedicle oblique fracture was found on the first thoracic vertebra. This injury is most certainly associated with the same mechanism producing the cervical ones. The absence of other injured body parts suggest a sudden and violent movement of the head and neck (in hyperextension), as is frequently seen in motor vehicle accidents.



Figure 3.9. Bilateral posterior arch fractures of C1 and C2 and bilateral laminar fracture of two other lower cervical vertebrae.

Case #16 NMNHS

The skeletal remains of this young 8 year-old boy were analysed. They were found to be fairly complete, although badly preserved. Epiphyses of almost all long bones and right fibula were absent, and bones from the upper body (including ribs, thoracic vertebrae and long bones) were also poorly preserved. Only one transverse fracture was found on the diaphysis of the right tibia at the middle third. Direction of applied force was not possible to determine, although a high energy direct impact is assumed. The circumstances associated with the death of this individual are difficult to predict solely on the basis of an isolated fracture of the tibia. A direct impact to this bone can be linked to vehicle-pedestrian accidents, but also to a fall from high height. However, in this last instance, more extensive injuries would be expected.

Case #17 NMNHS

This is the case of a 66 year-old female, whose skeletal remains were generally reasonably preserved (ribs and fibulae epiphysis were particularly poorly preserved) and in a reasonable state of conservation, except for the entire spinal column which was not present, as well as the sacrum and the right ischiopubic ramus. Trauma was identified in three body regions, with fractures recorded in four different bones/structures: the sternum, the ribs, the right hip bone and the left tibia. In the thoracic region, a transverse fracture was observed on the second intercostal space of the sternum. A fracture at this level is usually a consequence of a direct impact to the manubrium (anterior-posteriorly directed), with the upper portion of the sternum being pushed downward by the clavicle and first rib (Galloway, 1999). The rib cage

was also injured and oblique fractures were identified on the sternal end of ribs 2 to 4 on the left side. While ribs may have been fractured at the same time as the sternum, the former may also have been produced by lateral compression on the left side of the rib cage. In the pelvis and lumbar region, an acetabular transverse fracture on the right hip bone was observed. As the right ischiopubic ramus was not conserved, an associated fracture at this level cannot be identified. Nevertheless, acetabular transverse fractures are usually produced by a high load direct impact to the great trochanter (from right to left) or to the back of the pelvis (posterior-anteriorly directed) while the thigh is abducted (Fakler et al., 2007). The left tibia was the other injured bone, with a transverse fracture observed at the distal third of the diaphysis. A direct impact may have originated this injury although the morphology of the fracture does not allow determination of the direction of applied force. Considering the general trauma pattern of this case a fall from a high height appears to be a likely scenario, since there are multiple points of impact in different body regions, with all fractures requiring considerable force intensity to produce them.

Case #18 NMNHS

This is the case of a 74 year-old female whose skeletal remains were in a good condition of both preservation and conservation. The body of the sternum, the left pubis and the proximal third of the diaphysis of the left fibula were the major bones missing. Three body regions were injured (neurocranium, thorax and lower extremities), including fracturing of the occipital bone, right ribs, and both tibiae and fibulae. A linear fracture was observed on the right side of the occipital bone extending inferiorly to the foramen magnum. A direct impact to the occipital bone with mild force applied in a posterior-anterior direction would produce the observed trauma. In the thorax, incomplete fractures were found on the right ribs 10 (in between the middle to anterior third of the shaft) and 11 (on the posterior third of the shaft). An oblique fracture was registered on the posterior third of the shaft in the 12th right rib. These posteriorly located fractures on the lower ribs are most certainly related to a direct impact with a posterior-anterior direction (Di Maio and Di Maio, 2001). Trauma to the lower extremities was limited to the legs (thighs being spared). Butterfly fractures were observed on both tibiae at the middle of the diaphysis, suggesting a direct impact at this level and anterior-posteriorly directed. The right fibula exhibited a transverse fracture slightly below the level of the tibial fracture, and the left fibula showed an oblique fracture at the proximal third of the diaphysis. Both fibulae fractures seem linked to the event which produced the tibial lesions, with the fracture of the left fibula suggesting some degree of abduction of this bone (Teresinski, 2005). The pattern of injuries affecting both legs is highly suggestive of high-velocity events, particularly vehicle-pedestrian

accidents. The fractures observed on the posterior skull and rib cage are possibly the result of a subsequent fall.

Case #19 NMNHS

This is a young 20 year-old female whose skeletal remains were well preserved and complete. Evidence of perimortem trauma was found in five different body regions: cervical spine, shoulder girdle, thorax, pelvis and lumbar spine, and upper extremity. Atlas and axis were the only two cervical vertebrae injured, with the atlas exhibiting a fracture on the anterior-left and on posterior-right arches, dividing it in two. The axis showed a bilateral arch fracture and an incomplete fracture of the left superior articular facet. Trauma to both cervical vertebrae is associated with extreme movement of the head, inducing hyperextension of the neck. Some rotational force would also explain the unilateral facet fracture of the axis as well as the fracture pattern of the first cervical vertebra (Galloway, 1999). In what concerns the shoulder girdle, the right clavicle and the left scapula were the only bones affected. A butterfly fracture was observed on the middle third of the diaphysis in the right clavicle, suggesting a direct impact to this bone, anterior-posteriorly directed. The left scapula exhibited fracturing of the body, with a linear fracture extending from the suprascapular notch to the medial border and fracturing the superior border as well (Figure 3.10 A). Scapular fractures, particularly in the body, tend to be the result of high energy direct trauma and are frequently associated with first rib fractures, as crushing forces acting upon the posterior of the thorax bend the scapular body over them. Multiple and bilateral rib fractures were found. On the right side, oblique vertebral end fractures were observed on ribs 1-3, and sternal end oblique fractures on the first two ribs. On the left side, transverse fractures of the vertebral end were found on ribs 1 to 7. Oblique fractures were also observed on the sternal end of ribs 1 and 2. The left seventh rib presented an oblique fracture at the posterior third of the shaft. These injuries to the rib cage are compatible with a posterior high energy impact on the posterior of the body (anteriorly directed), most likely associated with the left scapula trauma as previously mentioned. In the pelvis and lumbar region, trauma was identified in L4 and L5, the sacrum and both hip bones. The two most inferior lumbar vertebrae showed transverse fractures of the spinous processes. This fracture is usually related to hyperextension motion of the spine (Baldwin and Ferrara, 2003). Trauma observed on the sacrum is described as a juxtaarticular fracture on the right side and as a lateral mass fracture on the left, according to the classification system of Schmidek and colleagues (1984). Pelvic fractures were found on the right os coxae presenting an iliac fracture with sacroiliac joint extension, and ischiopubic rami fractures on both sides. Pelvic and sacral fractures frequently occur in association. Considering the whole pattern in this case, lateral compression appears as the most likely mechanism, with force being applied to the anterior half

of the iliac wing, from right to left (Fakler et al., 2007). Trauma to the upper extremities only spared the right humerus. Although poorly preserved, a supracondylar “H” fracture was identified on the left humerus (Figure 3.10 B). This morphology is associated with a flexed position of the elbow to an angle of less than 90° (Jupiter, 1992). On the ipsilateral radius, a transverse fracture at the neck level (proximal fragment not conserved) was observed (Figure 3.10 B), while the left ulna exhibited an olecranon oblique fracture (Schatzker, 1987). Contrary to what is predicted above for the humeral fracture, the oblique fracture at the olecranon is usually related to hyperextension of the elbow. Nevertheless, elbow injuries are normally the result of indirect forces transmitted during falls onto the outstretched hand with the forearm pronated and in some degree of flexion (Galloway, 1999). On the right forearm, the fracture of distal right radius (Figure 3.10 C) resembles the chauffeur’s fracture morphology, being the result of impact forces driven to the radial styloid process (Galloway, 1999). The oblique fracture observed in the distal third of the ulnar diaphysis suggests a direct impact anterior-posteriorly directed (Figure 3.10 D). Although the precise mechanisms and force direction of each injury reported to this individual may not be asserted exactly, the pattern of trauma and the absence of injuries to the lower extremities suggest a fall from high height as the most likely circumstance of death.

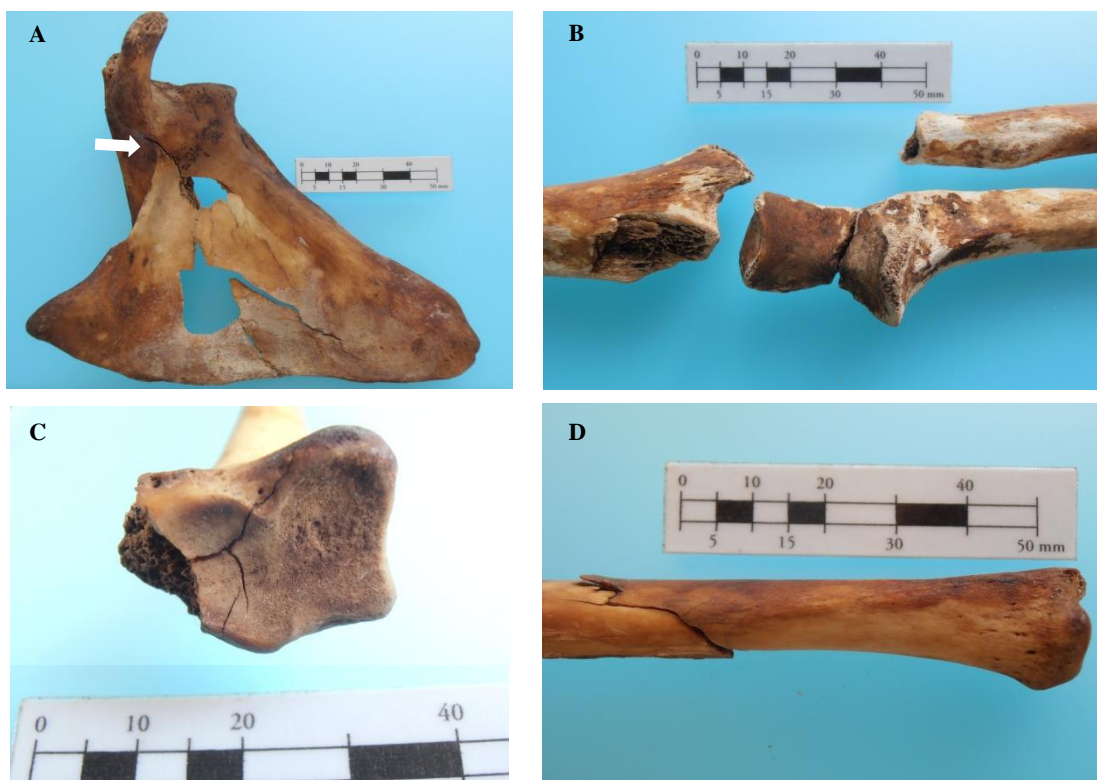

Figure 3.10. **A)** Linear fracture extending from the suprascapular notch (arrow) to the superior and medial borders of the body of the left scapula. **B)** Left upper extremity: supracondylar “H” fracture of the humerus, transverse fracture of the radial neck and olecranon oblique fracture of the ulna. **C)** Fracture of the right radial styloid process (inferior view, anterior is up). **D)** Oblique fracture of the distal third of the right ulna diaphysis.

Case #20 NMNHS

This is the case of a 42 year-old male, whose skeletal remains were in a poor state of conservation and preservation. Several vertebrae and the sternal body were absent and ribs were very fragmented. The left ischiopubic ramus was also not conserved and the remaining elements of the pelvis were poorly preserved. Perimortem trauma was observed in all body regions except for the shoulder girdle. The skull of this individual was severely injured, with all bones being affected by multiple linear and probable diastatic fractures, those being compatible with different points of impact and directions of applied force (at least anterior-posterior and posterior-anterior ones). At the viscerocranium, a tripod fracture was identified on the left zygomaticomaxillary complex, a linear fracture (sagittal plane) on the palatine process and also two fractures involving the mandible (body and subcondylar fractures – Figure 3.11 A and B). Both of these mandibular fractures are compatible with a single blow with point of impact on the mandibular body, slightly left to the midline and posteriorly (and possibly inferior-superiorly) directed. Trauma to the face was probably the result of a single event with a large surface impacting on the same parasagittal plane simultaneously on the mandible, maxilla and left zygomatic (anterior-posteriorly directed). Despite the poor state of preservation, bilateral fractures of the ribs were identified. Oblique fractures of the vertebral end of the first two ribs on both sides were observed, suggesting a high load applied on the posterior side of the rib cage. Fracturing of the sternal end of the second ribs (right and left) was also observed. Some lower ribs were fractured in an oblique and greenstick form on the posterior third of the body. Both os coxae exhibited signs of trauma, with an iliac fracture with sacroiliac joint extension on the right hip bone and an iliac wing fracture on the left hip bone (Fakler et al., 2007). Associated fractures on other elements of the pelvic girdle were impossible to identify as bones were badly preserved. Due to deficient preservation, interpretation of points of impact or even direction of force applied is compromised. Both humeri were fractured at approximately the same level - the proximal third of the diaphysis. On the right humerus, a butterfly fracture was identified suggesting a high energy force applied posteriorly and anteriorly directed. The morphology of the fracture in the left humerus was of a nearly transverse nature, again associated with a high load and direct impact, although direction of force is difficult to determine. An oblique fracture was also observed on the proximal diaphysis of the right third metacarpal, most certainly the result of a direct impact to the shaft (direction not assumed). At the lower extremities, segmental fractures were observed on the diaphysis of both femora (more proximally on the left and more distally on the right). The morphology resulted from multiple simultaneous fractures as a consequence of a high energy impact (most likely by a large flat surface). On the right tibia (at the level of the proximal metaphysis) an oblique fracture was observed, mostly likely the result of high intensity direct impact, although direction of applied force was difficult to assert. Both

fibulae had their diaphysis fractured at the level of the proximal third (oblique morphology), apparently as a result of direct impacts, both lateral-medially directed. Overall, this individual was involved in a high energy and high velocity impact event, probable against a large surface area, sectioning multiple bones, including both humeri and femora. A vehicle-pedestrian accident, involving a large and heavy vehicle, such as a train seems to be the most likely scenarios in this case.

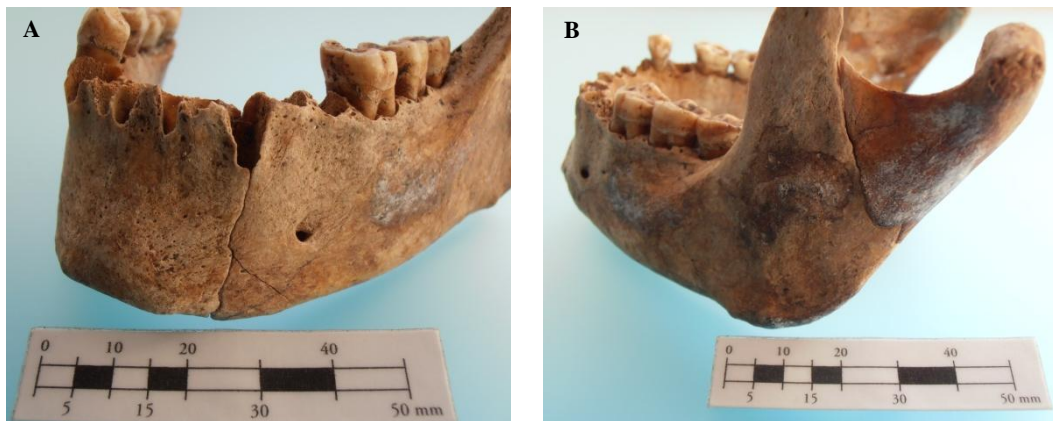


Figure 3.11. Body (A) and subcondylar (B) fractures on the left side of the mandible.

Case #21 NMNHS

The skeletal remains of this 52 year-old female were well preserved and conserved. Two vertebrae were missing (C1 and L2), as well as the sternum and both pubic rami. Evidence of trauma was recorded in the skull, seventh cervical vertebra, right clavicle and ribs from both sides. All bones comprising the neurocranium were involved with linear fractures produced by multiple impacts with different directions, including at least one anterior-posterior and one posterior-anterior. A tripod fracture was identified on the right zygomatic bone, which suggests an impact over the malar eminence. The same blow to the right malar eminence, if the result of a large surface impact, may have been on the origin of the Le Fort I fracture observed on the maxilla, which is usually produced by a lateral blow over the alveolar process (Galloway, 1999). Also, a body fracture, slightly anterior to the mandible right angle, is on the same anatomical plane as the two previously mentioned lesions. Fractures on the right side of the viscerocranium, involving the zygomatic, the maxilla and the mandible may have been the result of single high load impact with a large surface and right to left directed (and possibly anterior-posteriorly as well). Another fracture on the mandible body was observed slightly left to the midline. This fracture, being on the same parasagittal plane of two others linear fractures of the maxilla and frontal, is consistent with another single blow impacting simultaneously on these three mentioned bones (anterior-posterior direction). In the cervical spine, only a

transverse fracture of the spinous process of C7 was found. Mechanisms that may produce this type of fracture range from avulsion fractures, compression associated to extreme movements of rotation and extension of the head/neck or even direct trauma to the back of the neck (Shkrum, 1989). Its isolated occurrence prevents an assessment of the exact injury mechanism. The right clavicle showed a butterfly fracture on the middle of the diaphysis, compatible with a direct blow anterior-posteriorly directed. In the thorax, fractures were concentrated on the right side with only one incomplete fracture at the vertebral end of the second rib on the left side. On the right side, almost all ribs were injured, with ribs 1, 2, 4-6 and 9 exhibiting oblique fractures at the vertebral end. Ribs 3, 7 and 10 showed incomplete fractures of the vertebral end. Lesions were concentrated on the upper body and basically all suggest high energy impact, with multiple directions of applied force. With a pattern not typically or straightforwardly assigned to one or more specific circumstances, the most likely scenario will not be proposed.

3.2. The Circumstances of Death: Skeletal Findings *versus* Autopsy Reports

Once the skeletal remains were analysed, probable circumstances of death were proposed for each individual and based on the pattern of traumatic lesions identified. In Table 3.1, a direct comparison is established between the circumstances of death proposed (one or two) and those obtained from the autopsy reports held by the National Institute of Legal Medicine and Forensic Sciences, I.P. – Southern and Center Delegations. Agreement between both is coded as “Yes” if, at least, one of the proposed circumstances corresponds to the reported one; “No” if there is no agreement; and, “Similar” if the proposed circumstance is somehow related to the reported one but not strictly the same. Table summarizing the autopsy reports records is presented in Appendix B.

Table 3.1. Individual comparison of the circumstances of death proposed by the analysis of the skeletal remains with those reported on the autopsy records.

Case #	Circumstances of Death		Agreement (Yes/No/Similar)
	Proposed	Reported	
#1 CEI-UC	Fall from low height; Struck by an object	Assault by blunt object (homicidal)	Yes
#1 NMNHS	Motor vehicle accident; Fall from low height	Vehicle-pedestrian accident (car)	No
#2 NMNHS	Fall from high height	Fall from high height (4m)	Yes
#3 NMNHS	Vehicle-pedestrian accident	Vehicle-pedestrian accident (car)	Yes
#4 NMNHS	Vehicle-pedestrian accident	Vehicle-pedestrian accident (car)	Yes
#5 NMNHS	Struck by an object; Fall from low height	Vehicle-pedestrian accident (van)	No
#6 NMNHS	Fall from high height	Fall from height unknown (suicidal)	Similar
#7 NMNHS	Vehicle-pedestrian accident; Fall from high height	Vehicle-pedestrian accident (van)	Yes
#8 NMNHS	Struck by an object; Fall from high height	Fall from high height (bridge)	Yes
#9 NMNHS	Undetermined	Motor-vehicle accident	-
#10 NMNHS	Undetermined	Train-pedestrian accident	-
#11 NMNHS	Vehicle-pedestrian accident	Vehicle-pedal cyclist accident	Similar
#12 NMNHS	Vehicle-pedestrian accident	Vehicle-pedestrian accident	Yes
#13 NMNHS	Fall from high height	Fall from high height (wall)	Yes
#14 NMNHS	Motor vehicle accident; Fall from low height	Fall from low height (stairs)	Yes
#15 NMNHS	Motor vehicle accident	Struck by an object (accidental)	No
#16 NMNHS	Vehicle-pedestrian accident; Fall from high height	Vehicle-pedestrian accident (car)	Yes
#17 NMNHS	Fall from high height	Fall from height unknown (suicidal)	Similar
#18 NMNHS	Vehicle-pedestrian accident	Vehicle-pedestrian accident (car)	Yes
#19 NMNHS	Fall from high height	Fall from high height (bridge; suicidal)	Yes
#20 NMNHS	Train-pedestrian accident	Train-pedestrian accident	Yes
#21 NMNHS	Undetermined	Explosion and exposure to unspecified fire	-

In three out of 22 cases (13.6%), probable circumstances of death were not proposed. Agreement (“Yes”) was found for 13 cases (59.1%), while only three (13.6%) proposed circumstances did not match the reported one (“No”). For 5 out of 13 cases of agreement, two distinct probable circumstances were yet put forth. The three cases coded as “Similar” correspond to one individual who died as a consequence of a vehicle-pedal cyclist accident while the proposed circumstance was vehicle-pedestrian accident; and, the other two individuals, whose death was proposed as being associated to fall from high height, are reported falls in which the initial heights from which they occurred were unknown. The total distribution of the proposed (N=26) and the reported (N=22) circumstances of death is represented in Figure 3.12.

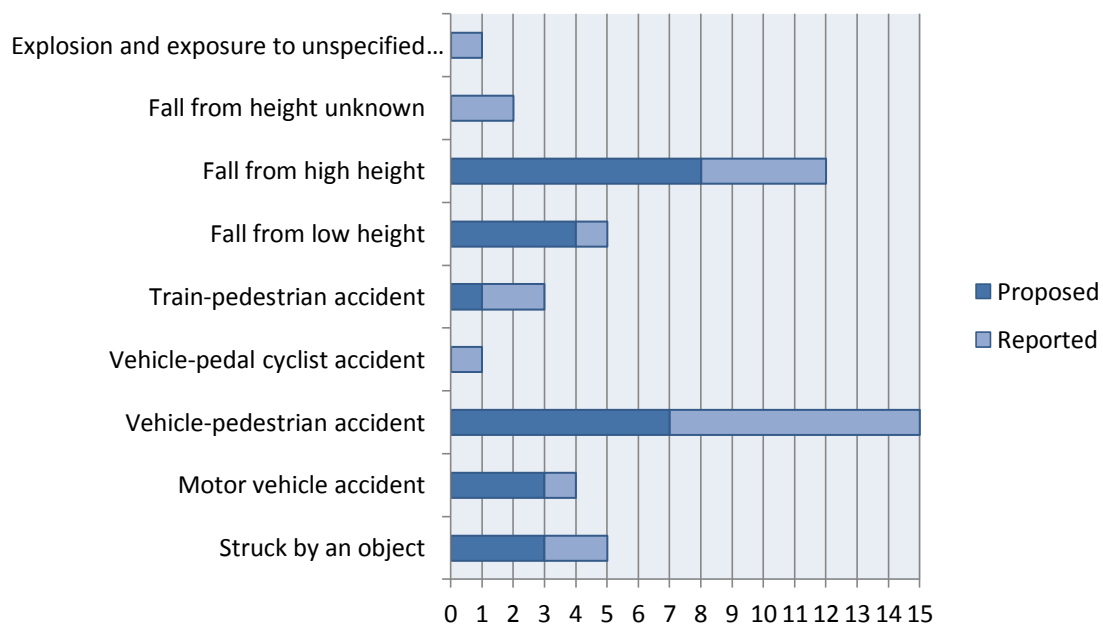


Figure 3.12. Distribution of the totality of circumstances of death, both proposed and reported.

Whilst individual #9 NMNHS had no circumstance of death being proposed due to insufficient findings to obtain a distinct trauma pattern, the analysis for individuals #10 and #21 NMNHS did not allow for a straightforward interpretation of a probable circumstance. Case #9 NMNHS is representative of the limitations when dealing with poorly preserved remains and scarcity of injuries to the skeleton. The anthropological analysis was, nonetheless, in harmony with the autopsy findings: rib fractures were the only skeletal injuries reported and the cause of death was internal bleeding due to traumatic lesions to the liver, as may have resulted from blunt force trauma as seen in a motor vehicle accident. On the contrary, individuals #10 and #21 NMNHS both presented massive skeletal injuries associated with high energy and velocity

impacts, although the multiplicity of points of impact and directions offers a pattern difficult to interpret. Though reported as a train-pedestrian accident, case #10 NMNHS differs from case #20 NMNHS (proposed and reported as train-pedestrian accident) in the extensiveness of traumatic findings. Comminution was found in both individuals, albeit in case #10 NMNHS it was mostly concentrated in the skull. Being aware of the real circumstance, one may presume that the individual was only lying on the railway on his head when he was hit by the advancing train. Consequently, the position of the individual, either standing or laying on the railway, will have a major influence on the trauma pattern produced, as well as the number of regions of the body involved. These factors weight considerably on the interpretation of the trauma based solely on the analysis of the skeletal remains.

Case #21 NMNHS represents an outlier in this sample as comprises the only case presumably involving blast force trauma. Although the autopsy records oddly report no trauma to the skeletal system, the anthropological study identified several fractures of perimortem nature (misidentification of the skeletal remains was discarded as being very unlikely). The reported cause of death was extensive burn associated to carbon monoxide poisoning, as a consequence of an explosion and exposure to unspecified fire. The typical findings associated with blast events as would be extensive and complex, comminuted fractures with numerous small, displaced bone splinters and fragments (Kimmerle and Baraybar, 2008) were not observed in this individual. Despite trauma to the skull involving multiple linear fractures, those are indicative of points of impact, which are frequently not identifiable in blast injuries (Kimmerle and Baraybar, 2008). Also, the butterfly configuration of ribs fractures associated to a response to the blast wave was not observed (Christensen and Smith, 2013). Instead, the lesions found and described in this case are typically the result of impact blunt forces and, therefore, may be associated to tertiary blast injuries, as a consequence from large objects falling onto the individual and/or if the individual is thrown into objects (Christensen et al., 2011).

The proposed circumstances for cases #1, #5 and #15 NMNHS did not correspond to the reported ones. These three individuals, whose skeletal remains, although fairly complete, only displayed a limited amount of unspecific injuries, hindering the understanding of the event. Besides, individuals #1 and #5 NMNHS, who actually died as a consequence of vehicle-pedestrian accident, showed no extensive injuries, namely to the lower extremities, as is common and distinctive of this type of circumstance (Saukko and Knight, 2004). Even in the case of a hit by a larger vehicle, like a truck, not involving the lower extremities at the level of the first impact, at least extensive lesions to the thoracic region would be expected (Tomczac and Buikstra, 1999). Again, the scarcity of injuries affecting the skeletal system draws attention to the limitations of the anthropological study by itself, with no further contextual information. It also highlights the specific features of each event, which is different from other similar

events, due to the nature, directions, velocity and magnitude of the force(s) involved. No two vehicle-pedestrian accidents, for example, are alike, due to various reasons, such as type of vehicle or point of impact.

Despite the aforementioned constraints, agreement between the proposed and the real circumstances was found for a total of 13 cases. Yet for 5 out of those 13, two circumstances could not be assigned to a single most probable scenario. Analysis of the patterns of trauma, particularly the regions of the body mostly affected in relation to each reported circumstance (at least, where there was more than one case to study) is summarized in Table 3.2.

The thorax was the most common region affected in the two individuals struck by an object. Of course the primary region will depend on the exact point of impact and the prevalence of injuries to the thorax is most likely related eventually to subsequent falls. The common feature to the cases of vehicle-pedestrian accidents is clearly the involvement of the lower extremities. This characteristic was preponderant during the analysis and the interpretation of the traumatic findings on the skeletal remains, as the engagement of the lower extremities, particularly legs, in vehicle-pedestrian accidents constitutes a recognised pattern in the literature (Galloway and Zephro, 2005; Li et al., 2013). The frequency of 3 out of 8 reported cases of vehicle-pedestrian accidents showing neurocranium and thorax injuries is probably related to second impacts, whether to the vehicle or the ground, after the individual being projected (Teresinski, 2005). Injuries to the thoracic region were common to the four reported cases of fall from high height. Besides, involvement of the neurocranium and viscerocranium in 3 out of these 4 cases is also in accordance with the literature, reporting trauma to the skull as a common feature (Atanasijevic et al., 2005; Hamel et al., 2013; Petaros et al., 2013).

Sample size in this research was too small to allow further analyses, as could have enlightened the similarities, patterns or trends occurring between different circumstances. It would have been interesting to have more cases allocated to each circumstance of death that allowed valuable comparisons between them, like distinguish fall from high height *versus* fall from low height, or even between heavy or light vehicle-pedestrian accidents. These distinctions would increase the medico-legal value of such anthropological study. Even so, this sample is of unique value since with archaeological material there is usually little room for corroboration of the proposed hypotheses, as it was feasible within the present investigation.

Table 3.2. Summarized features according to reported circumstances of death, namely, the minimum and maximum number (#) of injured body regions, and frequency (f) of each region being involved within the totality of cases allocated to each circumstance (N).

Circumstance	Body regions		f	N
	#	Regions		
Struck by an object	2	Neurocranium	1	2
		Cervical Spine	1	
		Thorax	2	
Motor vehicle accident	1	Thorax	-	1
Vehicle-pedestrian accident	1-4	Neurocranium	3	8
		Viscerocranium	2	
		Cervical Spine	1	
		Thorax	3	
		Pelvis and Lumbar	1	
		Upper Extremity	2	
Lower Extremity	6			
Vehicle-pedal cyclist accident	3	Thorax	-	1
		Pelvis and Lumbar		
		Lower Extremity		
Train-pedestrian accident	5-6	Neurocranium	2	2
		Viscerocranium	2	
		Thorax	2	
		Pelvis and Lumbar	1	
		Upper Extremity	2	
Lower Extremity	2			
Fall from low height	2	Neurocranium	-	1
		Cervical Spine		
Fall from high height	3-5	Neurocranium	3	4
		Viscerocranium	3	
		Cervical Spine	1	
		Shoulder Girdle	1	
		Thorax	4	
		Pelvis and Lumbar	1	
Upper Extremity	2			
Fall from height unknown	3	Cervical Spine	1	2
		Thorax	2	
		Pelvis and Lumbar	1	
		Upper Extremity	1	
		Lower Extremity	1	
Explosion and exposure to unspecified fire	5	Neurocranium	-	1
		Viscerocranium		
		Cervical Spine		
		Shoulder Girdle		
		Thorax		

Whereas speculations on possible cause of death are common within the archaeological literature, it is inappropriate for anthropologists to include such interpretations in a forensic case. Being aware that cause of death is a medical determination, there was no attempt in the present research to ascertain neither cause nor manner of death, which is the purview of the forensic pathology. Case #1 CEI-UC was the only one reported as a homicide (assault by blunt object), with the other cases from the NMNHS having manner of death reported as suicidal or accidental. Nevertheless, the observed lesions in the former did not allow the identification of a

situation of interpersonal violence, distinct from the accidental death of being struck by an object as in Case #15 NMNHS. Although there are some attempts in the literature to distinguish between accidental and suicidal falls (e.g. Christensen, 2004; Petaros et al., 2013), in this study, the intentionality of the fall did not reflect any particular pattern of the type or distribution of the lesions in the skeleton.

Instead, interpretations limited to the skeletal material included the opinion on the type of force, the direction and relative force, and the probable number of impacts that gave rise to the overall trauma. Links between individual injuries were discussed so that the probable mechanisms were addressed, while keeping in mind that the same fracture patterns can be consistent with more than one mechanism of injury. Attention was paid to the importance of an accurate interpretation of taphonomic indicators and also that a pattern of fracture usually associated with perimortem trauma it is not exclusively assigned to it. Perimortem features of a fracture are not always easy to interpret (e.g. Ubelaker and Adams, 1995; Sauer, 1998; Wheatley, 2008; Wieberg and Wescott, 2008) and that was certainly one of the challenges of this research. The possibility of a violent death leaving no evidence on the skeleton invalidates any attempt to reconstruct the events causing death solely from skeletal trauma analysis, as previously emphasized. It is within this context that the discussion of potentialities and limitations on the determination of the most probable circumstance of death must be laid out.

CHAPTER 4

***Final
Remarks***

As the field of forensic anthropology grows trauma analysis has started to play a vital component. The intent of this dissertation was to draw attention to some issues on trauma analysis, particularly trauma of blunt force nature. The review of the types and mechanisms of fracture production attempts to emphasize the importance of establishing and applying adequate protocols in the analysis of trauma in human skeletal remains. Trauma analysis must be settled in a careful and properly registered observation, and the interpretations must rely on validated scientific principles and methods. This analysis must be taken in a systematized way, with the intent of determining the mechanisms producing a specific lesion, as well as its temporal location in relation to the time of death which may, in the last instance, allow concluding about the circumstances of death of the individual. Depending on the state of preservation and completeness of the remains, one must accept the inability of reaching a definitive conclusion. In fact, the thorough explanation of a specific lesion is frequently not very straight and, in that cases, the equivocal results must be reported as so.

As a sub discipline of forensic anthropology and paleopathology, trauma analysis will continue to grow and evolve. There is a need for further research, both experimental and on existing cases, as there are still numerous unanswered questions. The uniqueness of documented osteological series as those studied here brings unpaired value to the advances in the field. Continued research will work to increase our knowledge of the mechanisms behind bone fracture patterns and better apply them particularly in medico-legal context. The investigators must accept that, more than ever, the study of trauma to the skeletal system demands multidisciplinary approaches with integration of the fields of anatomy and osteology, but also physics, biomechanics, ballistics and taphonomy.

Bibliography

- Anderson, L. D.; D'Alonzo, R. T. 1974. Fractures of the odontoid process of the axis. *Journal of Bone and Joint Surgery (Am)*, 56:1663-1674.
- Aufderheide, A. C.; Rodríguez-Martín, C. 1998. *The Cambridge Encyclopedia of Human Paleopathology*. Cambridge, Cambridge University Press.
- Atanasijevic, T. C.; Savic, S. N.; Nikolic, S. D.; Djoki, V. M. 2005. Frequency and severity of injuries in correlation with the height of fall. *Journal Forensic Science*, 50(3):608-612.
- Baldwin, N. G.; Ferrara, L. A. 2003. Biomechanics of thoracolumbar trauma. *Techniques in Neurosurgery*, 8(2):115-121.
- Berryman, H. E.; Symes, S. A. 1998. Recognizing gunshot and blunt cranialtrauma through fracture interpretation, In: Reichs, K.J. (ed.) *Forensic Osteology: Advances in the Identification of Human Remains*. Springfield, IL, Charles C. Thomas: 333-352.
- Cardoso, H. F. C. 2000. *Dimorfismo sexual na estatura, dimensões e proporções dos ossos longos dos membros. O caso de uma amostra Portuguesa dos séculos XIX-XX*. Master Dissertation in Human Evolution, Anthropology Department, University of Coimbra. (In Portuguese)
- Cardoso, H. F. V. 2005. *Patterns of growth and development of the human skeleton and dentition in relation to environmental quality: a biocultural analysis of a 20th century sample of Portuguese documented subadult skeletons*. PhD Dissertation in Anthropology, McMaster University.
- Cardoso, H. F. V. 2006a. Brief communication: the collection of identified human skeletons housed at the Bocage Museum (National Museum of Natural History), Lisbon, Portugal. *American Journal of Physical Anthropology*, 129: 173-176.
- Cardoso, H. F. V. 2006b. Elementos para a história da antropologia biológica em Portugal: O contributo do Museu Bocage (Museu Nacional de História Natural, Lisboa). *Trabalhos de Antropologia e Etnologia*, 46: 47-66. (In Portuguese)
- Christensen, A.M. 2004. The influence of behavior on freefall injury patterns: possible implications for forensic anthropological investigations. *Journal of Forensic Sciences*, 49(1): 5-10.
- Christensen, A. M.; Smith, V. A.; Ramos, V.; Shegogue, C.; Whitworth, M. 2011. Primary and Secondary Skeletal Blast Trauma. *Journal of Forensic Sciences*, 57: 1-6.
- Christensen, A. M.; Smith, V. A. 2013. Rib butterfly fractures as a possible indicator of blast trauma. *Journal of Forensic Sciences*, 58(S1): S15-S19.
- Cunha, E. 2006. Pathology as a factor of personal identity in forensic anthropology. In: Schmitt, A.; Cunha, E.; Pinheiro, J. (ed.) *Forensic Anthropology and Medicine: complementary sciences from recovery to cause of death*. Tottowa, Human Press: 333-358.
- Cunha, E.; Pinheiro, J. 2005/2006. A linguagem das fracturas: a perspectiva da Antropologia Forense. *Antropologia Portuguesa*, 22/23: 223-243.

- Curate, F. 2010. *O perímetro do declínio: Osteoporose e fracturas de fragilidade em três amostras osteológicas identificadas portuguesas – séculos XIX & XX*. PhD Dissertation in Biological Anthropology, University of Coimbra. (In Portuguese)
- Curate, F.; Lopes, C.; Cunha, E. 2010. A 14th-17th Century Osteoporotic Hip Fracture from the Santa Clara-a-Velha Convent in Coimbra (Portugal). *International Journal of Osteoarchaeology*, 20: 591-596.
- Daegling, D. J.; Warren, M. W.; Hotzman, J. L.; Self, C. J. 2008. Structural analysis of human rib fracture and implications for forensic interpretation. *Journal of Forensic Sciences*, 53: 1301–1307.
- Dequeker, J.; Ortner, D. J.; Stix, A. I.; Cheng, X.; Brys, P.; Boonen, S. 1997. Hip fracture and osteoporosis in a XIIth Dynasty female skeleton from Lisht, Upper Egypt. *Journal of Bone and Mineral Research*, 12(6): 881-888.
- Di Maio, V. J.; Di Maio, D. J. 2011. *Forensic pathology*. (2nd ed.) Boca Raton, FL, CRC Press.
- Dirkmaat, D. C.; Cabo, L. L.; Ousley, S. D.; Symes, S. A. 2008. New perspectives in forensic anthropology. *American Journal of Physical Anthropology*, 47: 33-52.
- Fakler, J. K. M.; Stahel, P. F.; Lundy, D. W. 2007. Classification of Pelvic Ring Injuries. In: Smith, W. R.; Ziran, B. H.; Morgan, S. J. (ed.) *Fractures of the Pelvis and Acetabulum*. Informa Healthcare USA, Inc.: 11-26.
- Fernandes, M. T. M. 1985. Coleções osteológicas. In: *Cem anos de antropologia em Coimbra, 1885–1985*. Coimbra: Museu e Laboratório Antropológico. p. 77–81.
- Galloway, A. 1999. *Broken Bones – Anthropological Analysis of Blunt Force Trauma*. (1st ed.) Illinois, Charles C. Thomas.
- Galloway, A.; Zephro, L. 2005. Skeletal Trauma Analysis of the Lower Extremity in Road Traffic Accidents, In: Rich, J.; Dean, D.E.; Powers, R.H. (eds.) *Forensic Medicine of the Lower Extremity - Human Identification and Trauma Analysis of the Thigh, Leg and Foot*. Tottowa, Human Press: 253-277.
- Guyomarc'h, P.; Campagna-Vaillancourt, M.; Kremer, C.; Sauvageau, A. 2010. Discrimination of falls and blows in blunt head trauma: a multi-criteria approach. *Journal of Forensic Sciences*, 55(2): 423-427.
- Hamel, A.; Llari, M.; Piercecchi- Marti, M.; Adalian, P.; Leonetti, G.; Thallon, L. 2013. Effects of fall conditions and biological variability on the mechanism of skull fractures caused by falls. *International Journal of Legal Medicine*, 127: 111-118.
- Hoke, R. S.; Chamberlain, D. 2004. Skeletal chest injuries secondary to cardiopulmonary resuscitation. *Resuscitation*, 63: 327–338.
- Jupiter, J. B. 1992. Trauma to the adult elbow and fractures of the distal humerus. In: Browner, B. D.; Jupiter, J. B.; Levine, A. M.; Trafton, P. G. (ed.) *Skeletal trauma fractures, dislocations, ligamentous injuries*. Philadelphia, W. B. Saunders Co.: 1125-1176.

- Kimmerle, E. H.; Baraybar, J. P. 2008. *Skeletal Trauma: Identification of Injuries Resulting from Human Rights Abuse and Armed Conflict*. Taylor & Francis.
- Kremer, C.; Racette, S.; Dionne, C.; Sauvageau, A. 2008. Discrimination of falls and blows in blunt head trauma: systematic study of the hat brim line rule in relation to skull fractures. *Journal of Forensic Sciences*, 53(3): 716-719.
- Kremer, C.; Sauvageau, A. 2009. Discrimination of Falls and Blows in Blunt Head Trauma: Assessment of Predictability Through Combined Criteria. *Journal of Forensic Sciences*, 54(4): 923-926.
- Kroman, A. M.; Symes, S. A. 2013. Investigation of Skeletal Trauma. In: DiGangi, E. A.; Moore, M. K. *Research Methods in Human Skeletal Biology*. Waltham, MA, Elsevier In.: 219-240.
- Kumar, V.; Abbas, A. K.; Fausto, N. 2005 [2004]. *Robbins e Cotran, Patologia – Bases Patológicas das Doenças*. (7 ed.) Rio de Janeiro, Elsevier.
- Li, Z.; Zou, D.; Liu, N.; Zhong, L.; Shao, Y.; Wan, L.; Huang, P.; Chen, Y. 2013. Finite element analysis of pedestrian lower limb fractures by direct force: The result of being run over or impact? *Forensic Science International*, 229(1-3): 43-51.
- Letournel, E. 1980. Acetabulum fractures: classification and management. *Clinical Orthopaedics and related research*, 151: 81-106.
- Lovell, N. C. 1997. Trauma Analysis in Paleopathology. *Yearbook of Physical Anthropology*, 40: 139-170.
- Love, J. C.; Symes, S. A. 2004. Understanding rib fracture patterns: incomplete and buckle fractures. *Journal of Forensic Sciences*, 49: 1153-1158.
- Miller, S. D.; Herbst, S. A. 2005. Ankle Fractures In: Calhoun, J.; Laughlin, R. T. (ed.) *Fractures of the Foot and Ankle Diagnosis and Treatment of Injury and Disease*. Taylor & Francis Group: 1-26.
- Moraitis, K.; Spiliopoulou, C. 2006. Identification and differential diagnosis of perimortem blunt force trauma in tubular long bones. *Forensic Science, Medicine, and Pathology*, 2(4): 221-229.
- Ortner, D. 2003. *Identification of pathological conditions in human skeletal remains*. (2th ed.) San Diego, Academic Press.
- Petaros, A.; Slaus, M.; Coklo, M.; Sosa, I.; Cengija, M.; Bosnar, A. 2013. Retrospective analysis of free-fall fractures with regard to height and cause of fall. *Forensic Science International*, 226(1-3): 290-295.
- Pinto, D. C.; Haden-Pinneri, K.; Love, J. C. 2013. Manual and Automated Cardiopulmonary Resuscitation (CPR): A Comparison of Associated Injury Patterns. *Journal of Forensic Sciences*, 58(4): 904-909.

- Resnick, D.; Goergen, T. G. 2004. Physical Injury: Concepts and Terminology. *In*: Resnick, D.; Kransdorf, M. J. (ed.) *Bone and Joint Imaging*. Philadelphia, Saunders: 789-830.
- Rodríguez-Martín, C. 2006. Identification and Differential Diagnosis of Traumatic Lesions of the Skeleton. *In*: Schmitt, A.; Cunha, E.; Pinheiro, J. (ed.) *Forensic Anthropology and Medicine: complementary sciences from recovery to cause of death*. Tottowa, Human Press: 196-221.
- Santos, A. L. 2000. *A Skeletal Picture of Tuberculosis. Macroscopic, radio- logical, biomolecular, and historical evidence from the Coimbra Identified Skeletal Collection*. PhD Dissertation in Biological Anthropology, Anthropology Department, University of Coimbra.
- Sauer, N. 1998. The timing of injuries and manner of death: distinguishing among antemortem, perimortem and postmortem trauma. *In*: Reichs, K. (ed.) *Forensic Osteology*. Springfield, Charles C. Thomas: 321-332.
- Saukko, P.; Knight, B. 2004. Transportation injuries. *In*: Bureau, S.; Vandenberg, L.; Ueberberg, A. (ed.) *Knight's Forensic Pathology*. London, Arnold: 293–294.
- Serra, L. M. A. 2001. *Critérios Fundamentais em Fracturas e Ortopedia*. (2 ed.) Lisboa, Lidel – Edições Técnicas.
- Schatzker, J. 1987. Fractures of the olecranon. *In*: Schatzker, J.; Tile, M. (ed.) *The rationale of operative fracture care*. Berlin, Springer-Verlag: 89-95.
- Schmid, H. H.; Smith, D. A.; Kristiansen, T. K. 1984. Sacral fractures. *Neurosurgery*, 15: 735-746.
- Shkrum, M. J.; Green, R. N.; Nowak, E. S. 1989. Upper Cervical Trauma in Motor Vehicle Collisions. *Journal of Forensic Sciences*, 34(2): 381-90.
- Swartz, J. D.; Curtin, H. D. 2003. Temporal Bone: Trauma, *In*: Som, P. M.; Curtin, H. D. (ed.) *Head and Neck Imaging*. St. Louis, Mosby: 1230-1244.
- SWGANTH. 2011. Trauma Analysis. *Scientific Working Group for Forensic Anthropology*, 1-7.
- Symes, S. A.; L'Abbé, E. N.; Chapman, E. N.; Wolff, I.; Dirkmaat, D. C. 2012. Interpreting Traumatic Injury to Bone in Medicolegal Investigations. *In*: Dirkmaat, D. C. (ed.) *A companion to Forensic Anthropology*. Chichester, UK, John Wiley & Sons, Ltd. doi: 10.1002/9781118255377.ch17
- Teresinski, G. 2005. Injuries of the Thigh, Knee, and Ankle as Reconstructive Factors in Road Traffic Accidents, *In*: Rich, J.; Dean, D. E.; Powers, R. H. (ed.) *Forensic Medicine of the Lower Extremity - Human Identification and Trauma Analysis of the Thigh, Leg, and Foot*. Tottowa, Human Press: 311-342.
- Tomczak, P. D.; Buikstra, J. E. 1999. Analysis of blunt trauma injuries: vertical deceleration versus horizontal deceleration injuries. *Journal of Forensic Sciences*, 44(2): 253-262.

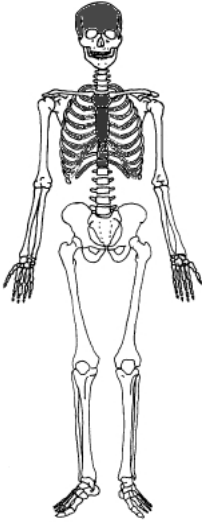
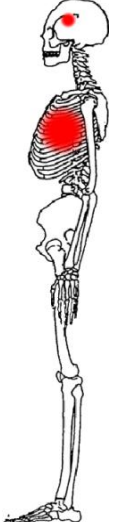
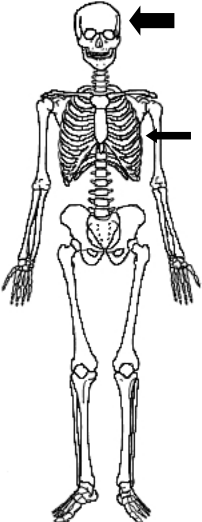
- Ubelaker, D. H.; Adams, B. J. 1995. Differentiation of perimortem and postmortem trauma using taphonomic indicators. *Journal of Forensic Sciences*, 40(3): 509-512.
- Waldron, T. 2009. *Paleopathology*. Cambridge Manuals in Archaeology. Cambridge, Cambridge University Press.
- Wheatley, B. P. 2008. Perimortem or postmortem bone fractures? An experimental study of fracture patterns in deer femora. *Journal of Forensic Sciences*, 53(1): 2-5.
- Wieberg, D. A. M.; Wescott, D. J. 2008. Estimating the timing of long bone fractures: correlation between the postmortem interval, bone moisture content, and blunt force trauma fracture characteristics. *Journal of Forensic Sciences*, 53(5): 1028-1034.

Appendices


Appendix A

Tables presented here contain summarized information of each individual skeletal remains analysis of perimortem blunt force trauma evidences. A total of 22 tables are presented, including one individual from the Coimbra Identified Skeletal Collection (Case #1 CEI-UC) and 21 individuals from the Lisbon Collection (Cases #1-#21 NMNHS). Each table provides descriptive data on the body regions presenting signs of trauma, individual fractured bones, laterality, types of fracture, points of impact (in case of direct trauma), force intensity (graded as “+” or “++”, as relatively lower or higher energy trauma), force direction and probable circumstances (one or more are proposed as the most likely circumstances of death). Above the descriptive data of each case, skeletal schematic representations are also provided: one scheme shows the body regions involved colored grey; one or more schemes shows dots that represents identified points of impact; and, one or more schemes shows directions of force through arrows (thinner or larger according to “+” or “++” force intensity, respectively). More detailed description on each case is presented on the “Results and Discussion” section.

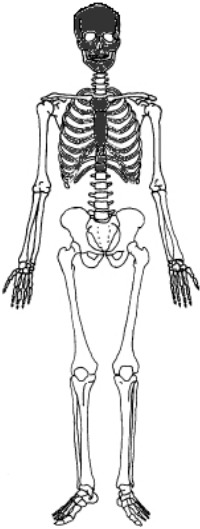
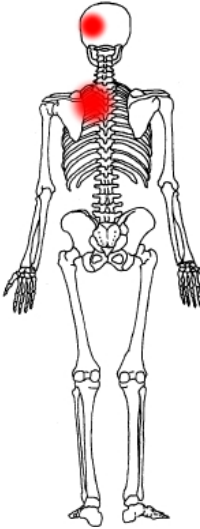

Case #1 CEI-UC (Male, 21yo)							
Body Region	Fractured Bones	Laterality	Type of Fracture	Point of Impact	Force Intensity	Force Direction	Probable Circumstances
Neurocranium	Parietal	Left	Linear	Left sphenoparietal suture (prox.)	++	Left-right	Fall from low height; Struck by an object
	Sphenoid						
Thorax	Ribs 2,4,11		Oblique	Lateral rib cage	+		

OBS. C1, C2 and C6 not conserved.

Case #1 NMNHS (Male, 40yo)							
Body Region	Fractured Bones	Laterality	Type of Fracture	Point of Impact	Force Intensity	Force Direction	Probable Circumstances
Cervical Spine	Atlas	-	Posterior arch, laminar and facet	Indirect trauma	++	Hyperextension, hyperflexion or inferior-superior	Motor vehicle accident; Fall from low height
	C?						
	C7						
							
OBS. Only 4 cervical vertebrae conserved; Axis poorly preserved.							

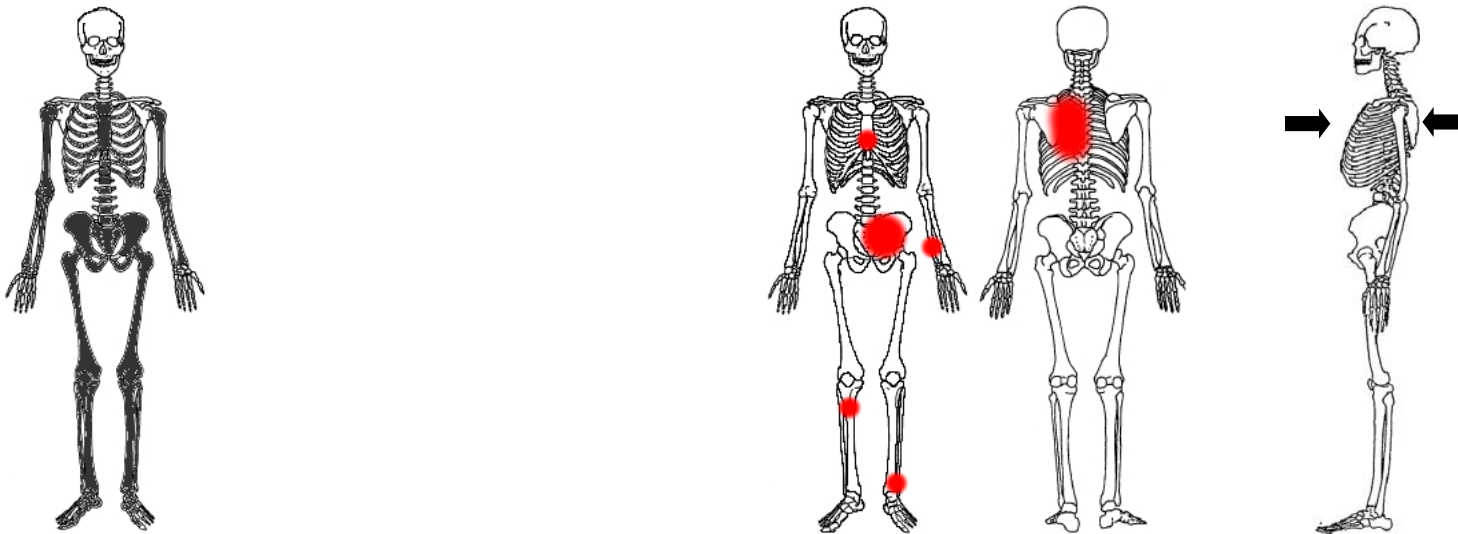
Case #2 NMNHS (Male, 51yo)							
Body Region	Fractured Bones	Laterality	Type of Fracture	Point of Impact	Force Intensity	Force Direction	Probable Circumstances
Neurocranium	Parietal	Left	Linear	Left parietal	++	Posterior-anterior	Fall from high height
	Temporal						
	Sphenoid						
Viscerocranium	Ethmoid	Bilateral	Linear				
	Palatine	Right					
Thorax	Ribs 2,3	Left	Transverse and greenstick	Posterior rib cage			

OBS. Skeleton generally poorly preserved; C1, C4, L2, L3, left clavicle and right pubic ramus not conserved.

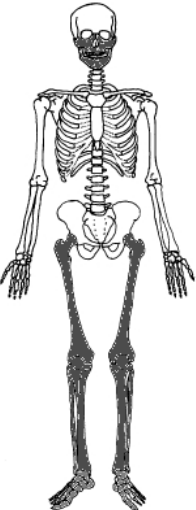
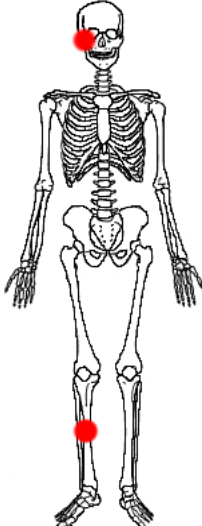
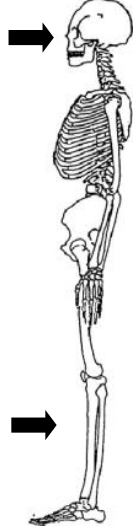
Case #3 NMNHS (Female, 55yo)

Body Region	Fractured Bones	Laterality	Type of Fracture	Point of Impact	Force Intensity	Force Direction	Probable Circumstances
Thorax	Ribs 1-4,9-11	Left	Oblique	Posterior rib cage	++	Posterior-anterior	Vehicle-pedestrian accident
	Sternum	-	Transverse	Body lower third		Anterior-posterior	
Pelvis and Lumbar	Sacrum	-	Comminuted	Undetermined		+	
	Hip bone	Left					
Upper Extremity	Ulna	Left	Oblique or butterfly	Diaphysis mid to distal third			
Lower Extremity	Tibia	Right	Comminuted	Diaphysis proximal third	++		
	Fibula	Left	Spiral	Indirect trauma	+		



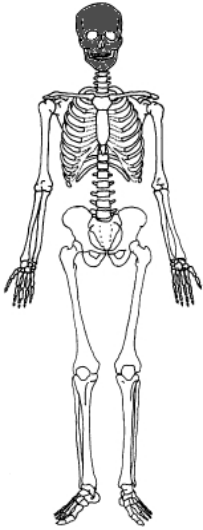
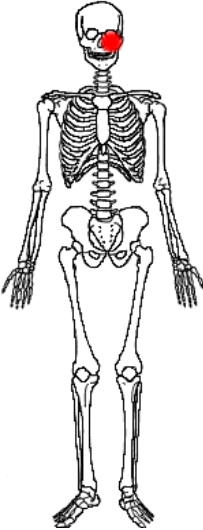

OBS. Left humerus, scapula and clavicle not conserved; Lumbar vertebrae and distal epiphysis of left tibia poorly preserved; Cranium poorly conserved.

Case #4 NMNHS (Male, 63yo)							
Body Region	Fractured Bones	Laterality	Type of Fracture	Point of Impact	Force Intensity	Force Direction	Probable Circumstances
Viscerocranium	Zygomatic	Right	Tripod	Malar eminence	++	Anterior-posterior and/or right-left	Vehicle-pedestrian accident
	Maxilla		Butterfly	Diaphysis mid third		Anterior-posterior	
Lower Extremity	Tibia		Spiral	Indirect trauma		Undetermined	

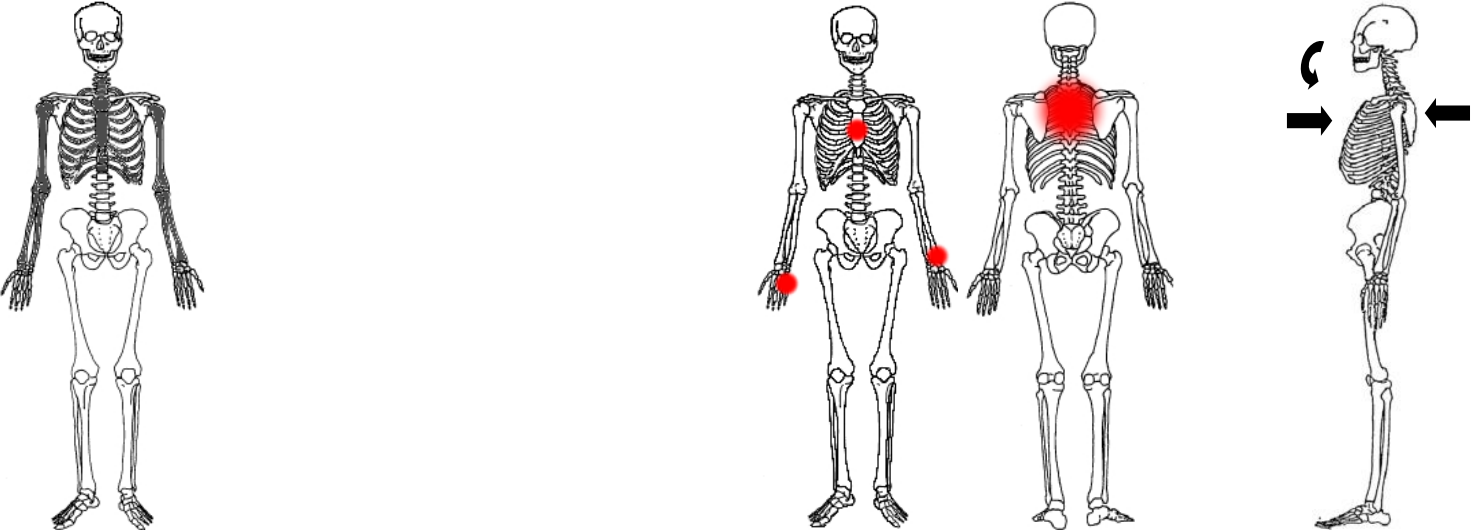
OBS. Manubrium of the sternum not conserved.

Case #5 NMNHS (Male, 33yo)							
Body Region	Fractured Bones	Laterality	Type of Fracture	Point of Impact	Force Intensity	Force Direction	Probable Circumstances
Neurocranium	Temporal	Left	Linear	Malar eminence	++	Anterior-posterior	Struck by an object; Fall from low height
	Sphenoid						
	Frontal						
	Zygomatic arch		Transverse				
Zygomatic process	Greenstick						
Viscerocranium	Zygomatic	Maxilla	Tripod				

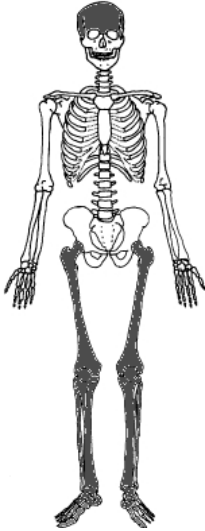
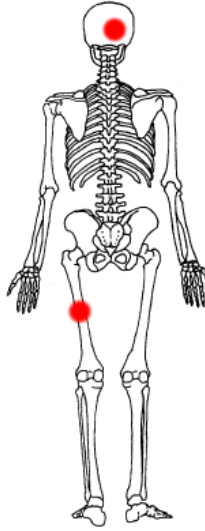

OBS. Left innominate not conserved.

Case #6 NMNHS (Male, 38yo)							
Body Region	Fractured Bones	Laterality	Type of Fracture	Point of Impact	Force Intensity	Force Direction	Probable Circumstances
Cervical Spine	C?	-	Lateral mass	Indirect trauma	++	Rotation and flexion	Fall from high height
	C7		Posterior arches				
Thorax	T4	-	Facet	Body mid third	++	Anterior-posterior	
	Sternum body		Transverse			Posterior-anterior	
	Ribs	2-5	Right	Oblique	Posterior rib cage	++	
		1-4	Left				
Upper Extremity	Radius	Left	Spiral	Distal epiphysis	+	Undetermined	
	Metacarpal 5	Right	Longitudinal	Metacarpal shaft			



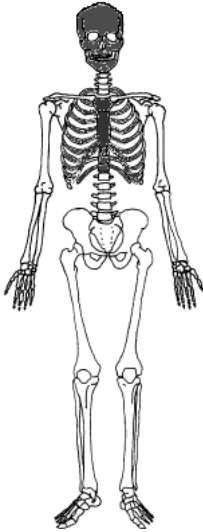

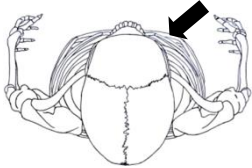
OBS. Vertebrae poorly preserved; Right first rib not conserved; Ulnae distal epiphyses poorly preserved.

Case #7 NMNHS (Male, 10yo)							
Body Region	Fractured Bones	Laterality	Type of Fracture	Point of Impact	Force Intensity	Force Direction	Probable Circumstances
Neurocranium	Occipital	Right	Linear	Occipital	++	Posterior-anterior	Vehicle-pedestrian accident; Fall from high height
	Parietal					Undetermined	
Lower Extremity	Femur	Left	Transverse	Mid diaphysis			

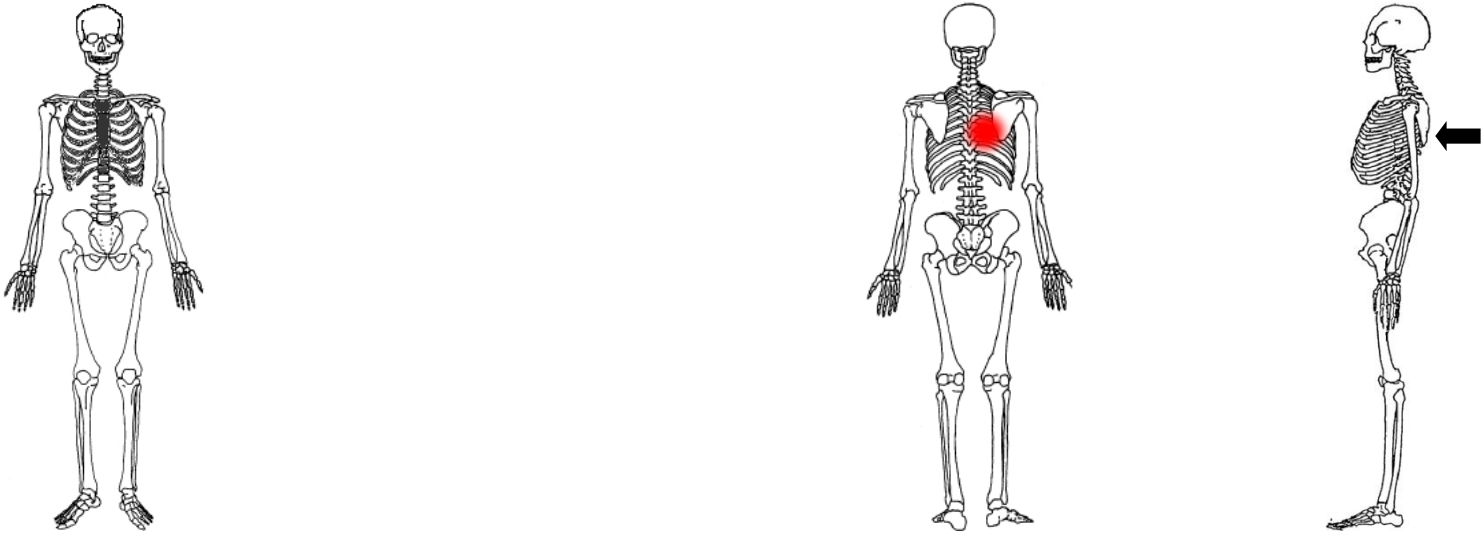




OBS. Non-adult skeletal remains poorly conserved and preserved.

Case #8 NMNHS (Male, 9yo)							
Body Region	Fractured Bones	Laterality	Type of Fracture	Point of Impact	Force Intensity	Force Direction	Probable Circumstances
Neurocranium	Occipital	Left	Linear	Frontal	++	Right-left and anterior-posterior	Struck by an object; Fall from high height
	Temporal petrous portion		Transverse				
	Frontal	Bilateral	Linear				
Viscerocranium	Maxilla	Bilateral	Linear				
	Ethmoid						
	Palatine	Left					
Thorax	Rib 6	Right	Greenstick	Undetermined	+	Undetermined	

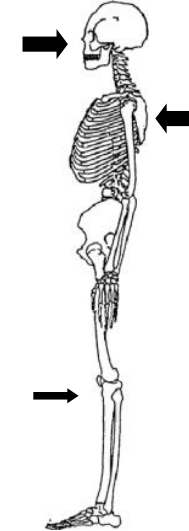
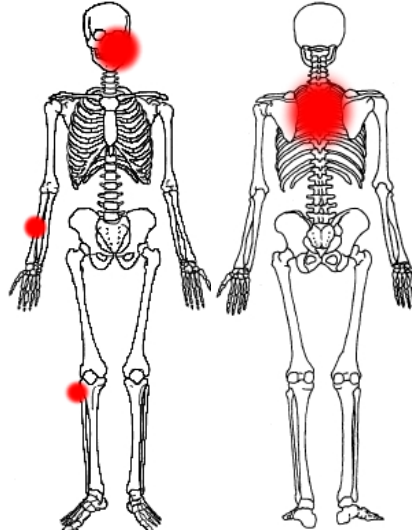
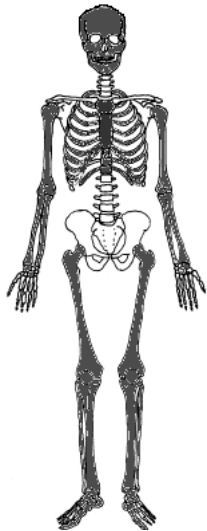




OBS. Nasal bones and some epiphyses not conserved.

Case #9 NMNHS (Male, 43yo)							
Body Region	Fractured Bones	Laterality	Type of Fracture	Point of Impact	Force Intensity	Force Direction	Probable Circumstances
Thorax	Ribs 6-8	Right	Oblique	Posterior rib cage (probable)	+	Posterior-anterior (probable)	Undetermined
							
OBS. Skeletal remains poorly preserved, particularly ribs.							

Case #10 NMNHS (Male, 40yo)

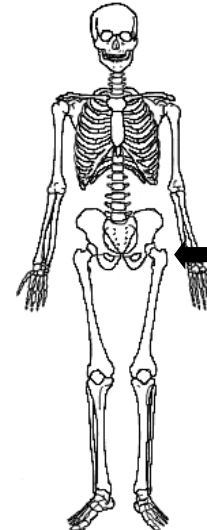
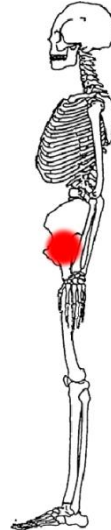
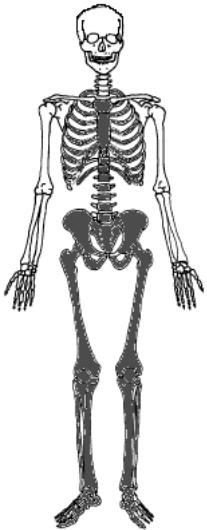
Body Region	Fractured Bones	Laterality	Type of Fracture	Point of Impact	Force Intensity	Force Direction	Probable Circumstances		
Neurocranium	Parietal	Right	Comminuted	Frontal, maxilla and mandible	++	Anterior-posterior	Undetermined		
	Frontal	Bilateral							
	Sphenoid		Comminuted						
	Zygomatic process	Left	Transverse						
Viscerocranium	Maxilla	Left	Transverse	Posterior rib cage	+	Medial-lateral			
	Mandible body								
Thorax	Ribs	2-10	Oblique, butterfly and greenstick			Posterior rib cage		+	Posterior-anterior
		5-7							
Upper Extremity	Radius	Right	Butterfly	Diaphysis mid-proximal third	+	Medial-lateral			
Lower Extremity	Fibula		Oblique	Proximal epiphysis		Anterior-posterior			



OBS. Facial bones poorly conserved; Both first ribs and C2 not conserved.

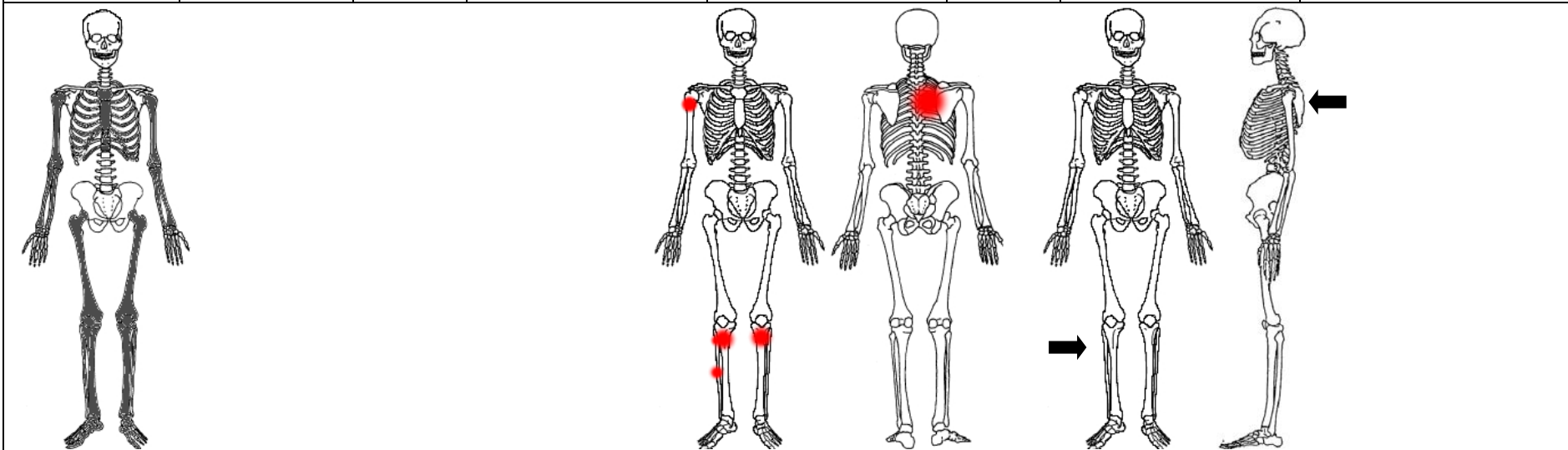
Case #11 NMNHS (Male, 27yo)

Body Region	Fractured Bones	Laterality	Type of Fracture	Point of Impact	Force Intensity	Force Direction	Probable Circumstances
Thorax	Rib 8	Left	Oblique	Anterior chest (probable)	+	Anterior-posterior (probable)	Vehicle-pedestrian accident
Pelvis and Lumbar	Sacrum		Lateral mass	Lateral (great trochanter)	++	Left-right	
	Hip bone		Acetabular T-shaped fracture and pubis symphysis separation				
Lower Extremity	Tibia		Avulsion of anterior cruciate ligament, incomplete wedge fracture of medial condyle and medial malleolus fracture	Indirect trauma	++	Undetermined	
	Fibula	Oblique					




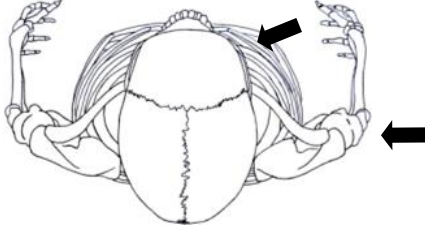
OBS. Skeletal remains well preserved and conserved.

Case #12 NMNHS (Female, 49yo)							
Body Region	Fractured Bones	Laterality	Type of Fracture	Point of Impact	Force Intensity	Force Direction	Probable Circumstances
Thorax	Ribs 3-6	Right	Oblique	Posterior rib cage (probable)	+	Posterior-anterior (probable)	Vehicle-pedestrian accident
Upper Extremity	Humerus	Right	Transverse	Diaphysis proximal third	++	Undetermined	
Lower Extremity	Tibia	Right	Transverse	Diaphysis proximal third	++	Right-left	
		Left	Oblique				
	Fibula	Right	Transverse and butterfly	Diaphysis proximal and mid third			
Left		Transverse	Proximal epiphysis				



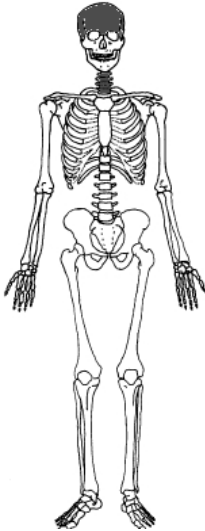

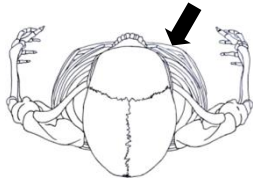
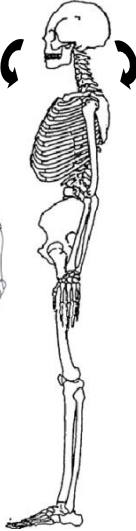
OBS. Skeletal remains poorly conserved and preserved; Cervical spine and sternum not conserved; Proximal epiphyses of right radius and ulna not conserved; Distal epiphyses of tibiae poorly preserved.

Case #13 NMNHS (Male, 63yo)							
Body Region	Fractured Bones	Laterality	Type of Fracture	Point of Impact	Force Intensity	Force Direction	Probable Circumstances
Neurocranium	Frontal	Right	Linear	Frontal	++	Anterior-posterior and right-left	Fall from high height
	Sphenoid	Bilateral	Comminuted				
	Temporal	Left	Longitudinal				
Viscerocranium	Zygomatic	Right	Tripod	Malar eminence			
	Maxilla						
Thorax	Rib 1	Right	Transverse and oblique	Undetermined		Undetermined	
	T1	-	Right transverse process greenstick fracture				
Upper Extremity	Humerus	Right	Comminuted	Diaphysis mid-proximal third	Right-left (probable)		

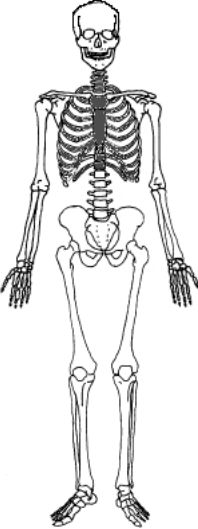

OBS. Right pubic ramus and distal epiphyses of radii not conserved.

Case #14 NMNHS (Female, 82yo)							
Body Region	Fractured Bones	Laterality	Type of Fracture	Point of Impact	Force Intensity	Force Direction	Probable Circumstances
Neurocranium	Frontal	Bilateral	Linear	Frontal	++	Right-left and anterior-posterior	Motor vehicle accident; Fall from low height
	Sphenoid	Right				Hyperflexion or hyperextension	
Cervical Spinal	Axis		-	Transverse odontoid and C2 body	Indirect trauma		







OBS. Right radius not conserved and right ulna poorly preserved.

Case #15 NMNHS (Male, 52yo)							
Body Region	Fractured Bones	Laterality	Type of Fracture	Point of Impact	Force Intensity	Force Direction	Probable Circumstances
Cervical spine	Atlas	-	Posterior arch	Indirect trauma	++	Hyperextension	Motor vehicle accident
	Axis		Laminar				
	C?						
C?							
Thorax	T1		Left pedicle oblique				

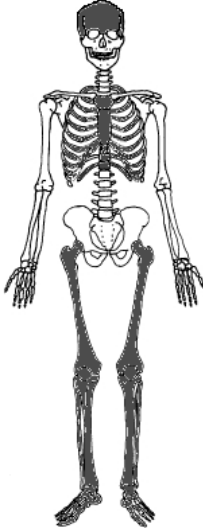
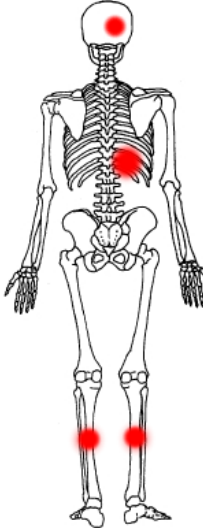
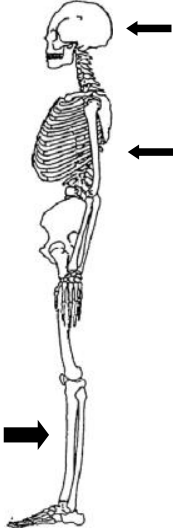



OBS. Only 4 cervical vertebrae conserved; Only a small fragment of both ischiopubic rami was conserved.

Case #16 NMNHS (Male, 8yo)							
Body Region	Fractured Bones	Laterality	Type of Fracture	Point of Impact	Force Intensity	Force Direction	Probable Circumstances
Lower Extremity	Tibia	Right	Transverse	Diaphysis mid third	++	Undetermined	Vehicle-pedestrian accident; Fall from high height
							
OBS. Non-adult skeletal remains poorly preserved, particularly ribs and vertebrae; Right fibula not conserved.							

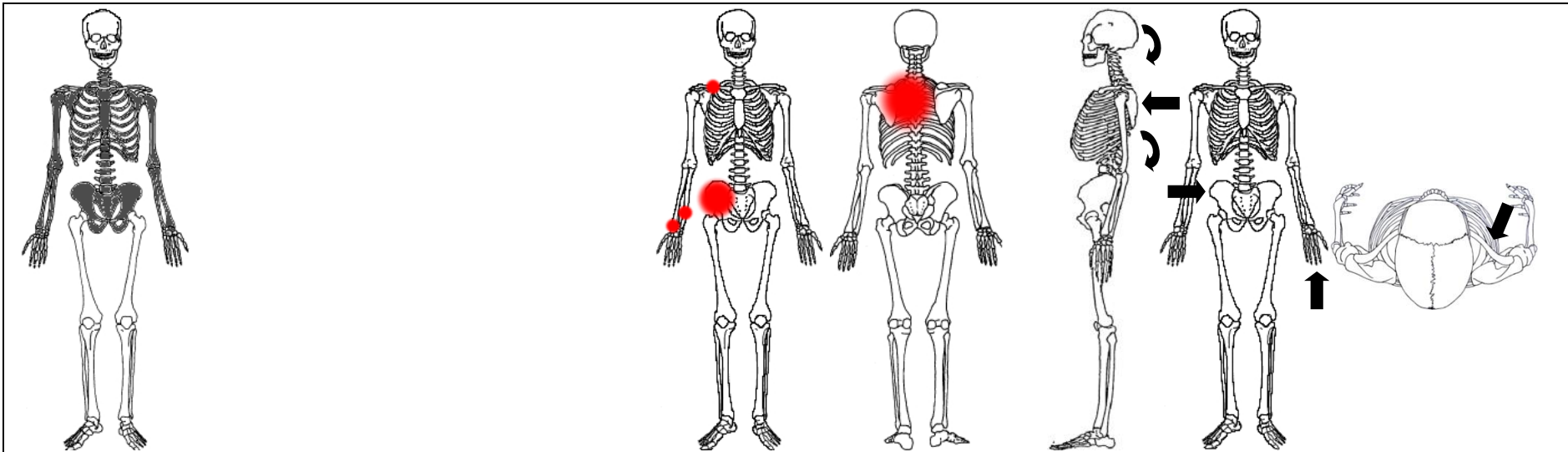
Case #17 NMNHS (Female, 66yo)							
Body Region	Fractured Bones	Laterality	Type of Fracture	Point of Impact	Force Intensity	Force Direction	Probable Circumstances
Thorax	Sternum	-	Transverse	Manubrium	++	Anterior-posterior	Fall from high height
	Ribs 2-4	Left	Oblique	Undetermined		Undetermined	
Pelvis and lumbar	Hip bone	Right	Acetabular transverse	Undetermined			
Lower extremity	Tibia	Left	Transverse	Diaphysis distal third			
OBS. Vertebral column, sacrum and right ischiopubic ramus not conserved; Fibulae epiphyses poorly preserved.							

Case #18 NMNHS (Female, 74yo)							
Body Region	Fractured Bones	Laterality	Type of Fracture	Point of Impact	Force Intensity	Force Direction	Probable Circumstances
Neurocranium	Occipital	Right	Linear	Occipital	+	Posterior-anterior	Vehicle-pedestrian accident
Thorax	Ribs 10-12		Oblique and greenstick	Posterior rib cage			
Lower Extremity	Tibia	Bilateral	Butterfly	Mid diaphysis	++	Anterior-posterior	
	Fibula	Right	Transverse	Indirect trauma			
		Left	Oblique				

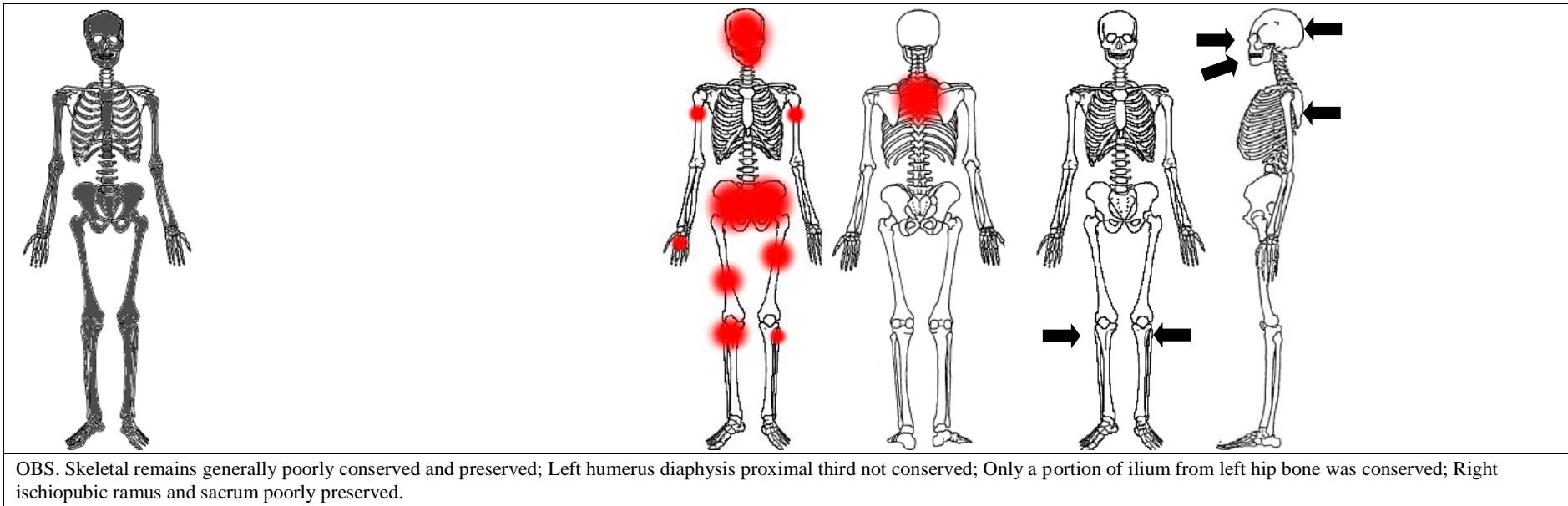
OBS. Left pubis and diaphysis proximal third of left fibula were not conserved; Manubrium was the only portion of the sternum conserved.

Case #19 NMNHS (Female, 20yo)								
Body Region	Fractured Bones		Laterality	Type of Fracture	Point of Impact	Force Intensity	Force Direction	Probable Circumstances
Cervical spine	Atlas		-	Anterior and posterior arches (two parts)	Indirect trauma	++	Hyperextension and rotation	Fall from high height
	Axis			Bilateral arch and incomplete left facet				
Shoulder girdle	Clavicle		Right	Butterfly	Diaphysis mid third		Anterior-posterior	
	Scapula		Left	Body linear	Posterior shoulder region			
Thorax	Ribs	1-3	Right	Oblique, transverse and greenstick	Posterior rib cage		Posterior-anterior	
		1-7	Left					
Pelvis and Lumbar	L4		-	Spinous process transverse	Indirect trauma		Hyperextension	
	L5			Lateral mass and juxtaarticular	Laterally (anterior half of the iliac wing)			
	Sacrum			Right			Iliac fracture with sacroiliac joint extension, and ischiopubic ramus fracture	
	Hip bone		Left	Ischiopubic ramus				
Upper Extremity	Humerus		Left	Supracondylar "H"	Indirect trauma	Distal-proximal		
	Ulna	Right		Oblique	Diaphysis distal third	Anterior-posterior		
		Left		Olecranon oblique	Indirect trauma	Distal-proximal		
	Radius	Right		Chauffeur's fracture	Distal epiphysis	Undetermined		
		Left		Neck transverse	Indirect trauma	Distal-proximal		

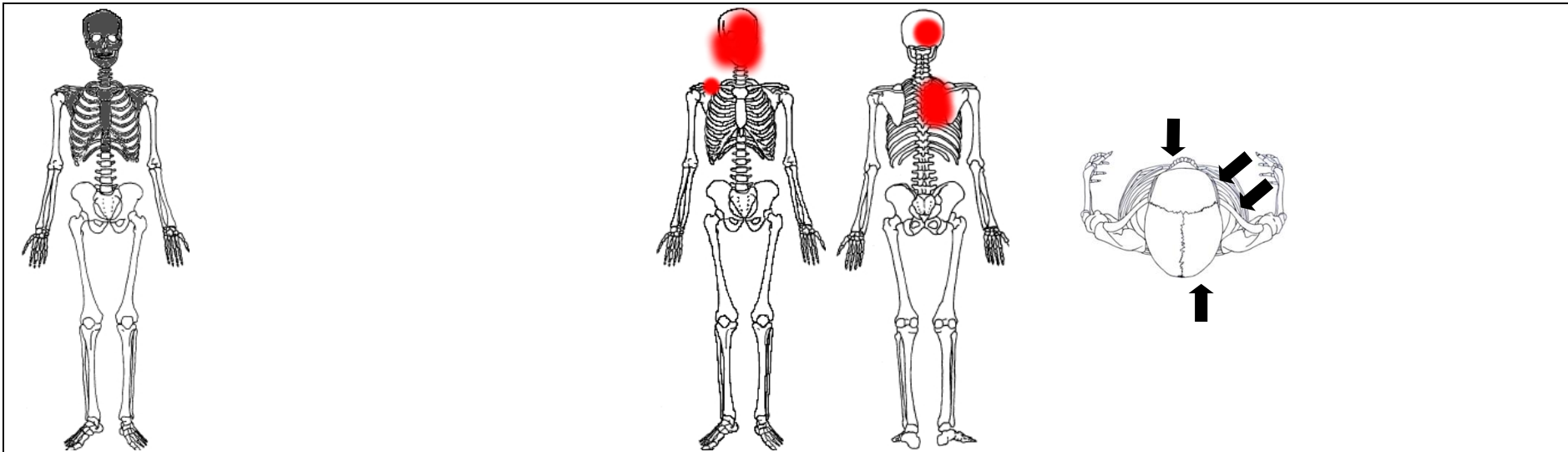


OBS. Manubrium was the only portion of the sternum conserved.

Case #20 NMNHS (Male, 42yo)							
Body Region	Fractured Bones	Laterality	Type of Fracture	Point of Impact	Force Intensity	Force Direction	Probable Circumstances
Neurocranium	Frontal	Bilateral	Linear	Multiple	++	Anterior-posterior and posterior-anterior (possibly more)	Train-pedestrian accident
	Parietal						
	Sphenoid	Left					
	Occipital						
	Temporal						
Viscerocranium	Palatine process	Bilateral	Linear	Maxilla			
	Zygomatic	Left	Tripod	Malar eminence			
	Mandible		Body and ascending ramus	Body			
Thorax	Ribs 1,2 (+ others unidentified)	Bilateral	Oblique and greenstick	Posterior rib cage			
Pelvis and Lumbar	Hip bone	Right	Iliac fracture with sacroiliac joint extension	Undetermined			
		Left	Iliac wing				
Upper Extremity	Humerus	Right	Butterfly	Diaphysis proximal third			
		Left	Transverse				
	Metacarpal 3	Right	Oblique	Proximal shaft	+	Undetermined	
Lower Extremity	Femur	Bilateral	Segmental	Diaphysis mid third	++	Undetermined	
	Tibia	Right	Oblique	Diaphysis proximal third			
	Fibula	Bilateral					



Case #21 NMNHS (Female, 52yo)							
Body Region	Fractured Bones	Laterality	Type of Fracture	Point of Impact	Force Intensity	Force Direction	Probable Circumstances
Neurocranium	Frontal	Bilateral	Linear	Frontal and occipital (multiple)	++	Anterior-posterior and posterior-anterior	Undetermined
	Parietal						
	Occipital						
	Temporal						
	Sphenoid						
Viscerocranium	Zygomatic	Right	Tripod	Malar eminence	++	Right-left and anterior-posterior	
	Maxilla	Bilateral	Le Fort I and vertical fractures	Alveolar process			
	Mandible		Body fractures	Body left and right sides			
Cervical spine	C7	-	Spinous process transverse	Indirect trauma	+	Undetermined	
Shoulder girdle	Clavicle	Right	Butterfly	Mid diaphysis	++	Anterior-posterior	
Thorax	Ribs	1-7,9,10	Right	Oblique and greenstick		Posterior rib cage	Posterior-anterior
		2	Left	Greenstick			



OBS. C1, L2, sternum and pubic rami not conserved.

Appendix B

Table presented here contain summarized information on the autopsy records of each individual analysed. A total of 22 cases are presented, including one individual from the Coimbra Identified Skeletal Collection (Case #1 CEI-UC) and 21 individuals from the Lisbon Collection (Cases #1-#21 NMNHS). A resume on the body regions presenting signs of trauma, autopsy traumatic findings to the skeletal system, determined cause of death and reported circumstance of death is presented.

Case #	Body Region	Skeletal Trauma	Cause of Death	Circumstance of Death
#1 CEI-UC	Neurocranium	Left parietal, temporal and greater wing of sphenoid bones.	Middle meningeal artery rupture; extradural haematoma.	Assault by blunt object on the left temporal region (homicidal)
#1 NMNHS	Cervical Spine	Odontoid and C2 body fracture and luxation of C2-C3.	Severe spinal-medullary traumatic lesions (spinal fracture with laceration of the spinal cord).	Vehicle-pedestrian accident (car)
#2 NMNHS	Neurocranium Shoulder Girdle Thorax	Linear fracture of the anterior-posterior quadrant of the left parietal bone, radiating to the base through the ipsilateral temporal bone to the right sphenoid bone and orbital roof. Linear fracture of the left half of the ethmoid's cribriform plate. Fracture of the posterior arch of all left ribs and of the 5 th and 6 th ipsilateral ribs on the anterior axillary line. Fracture of the vertebral end of the 1 st right rib and anterior arches of the ipsilateral 5 th and 7 th ribs. Transverse fracture on the lateral third of the left clavicle.	Severe cranioencephalic traumatic injuries (fracture of the skull with laceration of the brain; subdural haemorrhage).	Fall from high height (work accident, from a roof of about 4m height)
#3 NMNHS	Cervical Spine Thorax Lower Extremity	Luxation of the atlas-occipital and C7-T1 and fracture of the 10 th thoracic vertebra; multiple fractures of all ribs; comminuted fracture of the pelvic bones; luxation of the bones of the right elbow; fracture of both bones of the right leg, 38 cm above the ankle; luxation of the left talus-tibial and talus-fibular joints, with fracture of the left medial malleolus.	Severe traumatic injuries to the medulla oblongata.	Vehicle-pedestrian accident (car)
#4 NMNHS	Lower Extremity	Fracture of the middle third of the right tibia and fibula.	Shock as a result of the traumatic injuries (subdural haematoma; fracture of the right tibia and fibula).	Vehicle-pedestrian accident (car)
#5 NMNHS	-	No skeletal trauma reported.	Cranioencephalic trauma (head contusion, brain haemorrhage and laceration).	Vehicle-pedestrian accident (van)
#6 NMNHS	Cervical Spine Thorax Upper Extremity	Comminuted fracture of the sternum; comminuted fracture of the 3 rd , 4 th and 5 th cervical vertebrae and 5 th thoracic vertebra; fracture of the 8 th thoracic vertebra; fracture of the intermediate and distal phalanxes of the right 5 th finger.	Fracture of the cervical spine with section of the medulla; rupture of the heart.	Fall from height unknown (suicidal)
#7 NMNHS	Neurocranium Lower Extremity	Linear fracture of the right side of the occipital squama, extending to the foramen magnum; transverse fracture of the middle portion of the left femur.	Severe cranioencephalic traumatic injuries (brain contusion due to fracture of the cranium).	Vehicle-pedestrian accident (van)

#8 NMNHS	Neurocranium Thorax	Splintery fracture with sinking of the right half of the frontal bone, with oblique irradiation to the left and posterior, branching to the petrous portion of the left temporal bone and to the foramen magnum, the cribriform plate of the ethmoid bone and the intra-cranial side of the left orbit's roof showing multiple fracture lines that join the one already described; fracture of the 6 th rib on the right posterior axillary line.	Severe cranioencephalic traumatic injuries (cranial fracture with laceration of the brain).	Fall from high height (bridge)
#9 NMNHS	Thorax	Fracture of the anterior arch of the right ribs 2 to 6.	Haemorrhage due to severe traumatic injuries to the liver.	Motor-vehicle accident (collision of the car he was driving with a van)
#10 NMNHS	Neurocranium Viscerocranium Thorax	Comminuted fracture of the right frontal, sphenoid and parietal bones and all facial bones; fracture of the 3 rd , 4 th and 5 th ribs on the left anterior axillary line and the first 8 right ribs on the scapular line.	Severe cranioencephalic traumatic injuries.	Train-pedestrian accident
#11 NMNHS	Pelvis and Lumbar Lower Extremity	Luxation of the left sacroiliac joint; multiple fractures of the left pubic ramus; fracture of both bones of the left leg at the distal end with luxation of the tibia-talus joint.	Traumatic shock.	Vehicle-pedal cyclist accident (car)
#12 NMNHS	Thorax Lower Extremity	Luxation of the C3-C4, C7-T1 and T12-L1; fracture of the body of the sternum at the second intercostal space; fracture of the left ribs 1 to 6 and right ribs 1 and 2 at the middle clavicular line and of the right ribs 2 to 8 at the middle axillary line; fracture of the left tibia and fibula on the proximal third, 34 cm above the ankle; Splintery fracture of the right tibia and fibula on the proximal third, 32 cm above the ankle, and right fibula, on the middle third, 26 cm above the ankle.	Severe brain traumatic injuries (contusion with subdural haemorrhage)	Vehicle-pedestrian accident (car)
#13 NMNHS	Neurocranium Thorax Upper Extremity	Transverse fracture of the base of the skull base at the anterior cranial fossa, affecting both sides of the frontal bone, greater wings of the sphenoid and sella turcica; fracture of the orbit right's roof; fractures of the first 8 right ribs at the nipple line; fracture of the left ribs 1, 2 and 6 at the level of the anterior axillary line; Fracture of the right humerus at the union of the middle third with the proximal third.	Severe cranioencephalic traumatic injuries (brain contusion due to fracture of the cranium).	Fall from high height (wall)

#14 NMNHS	Neurocranium	Linear fracture of the frontal squama, the right temporal bone and the right greater wing of the sphenoid bone, Luxation of the C3-C4.	Cranioencephalic traumatic injuries and of the spine and spinal cord.	Fall from low height (stairs)
#15 NMNHS	Cervical Spine Pelvis and Lumbar	C2 fracture and luxation of the C2-C3; bilateral luxation of the sacroiliac joint and pubic symphysis and fracture of the left pubic ramus.	Bronchopneumonia as a complication of the severe traumatic injuries.	Struck by an object (work accident, with a metal plate)
#16 NMNHS	Thorax Lower Extremity	Fracture of the 9 th and 10 th ribs on the left posterior axillary line; fracture of the right tibia and fibula at the union of the middle third with the proximal third.	Traumatic injuries of the brain, associated with internal bleeding caused by traumatic tear of the spleen.	Vehicle-pedestrian accident (car)
#17 NMNHS	Thorax Pelvis and Lumbar Lower Extremity	Transverse fracture of the sternum at the second intercostal space; Fracture of the left ribs 2 to 5 along the costal cartilage; Vertical fracture on both sides of the sacrum, vertical fracture of the right pubic ramus and dislocation of pubic symphysis; Fracture of the distal end of both tibiae.	Traumatic rupture of the heart, associated with other severe traumatic injuries.	Fall from height unknown (suicidal, possibly after hanging attempt)
#18 NMNHS	Neurocranium Thorax Lower Extremity	Linear fracture of the occipital bone; fracture of the sternum; bilateral fracture of the 6 th , 7 th , and 8 th costal cartilages; Compound fractures of both tibiae and fibulae.	Cranioencephalic traumatic injuries (fracture of the skull and contusion and laceration of the brain).	Vehicle-pedestrian accident (car)
#19 NMNHS	Shoulder Girdle Thorax Pelvis and Lumbar Upper Extremity	Fractures of the lateral arch of the 1 st and 2 nd ribs and left posterior arch of the first 6 left ribs and first 4 ribs on the right side; fracture of the right clavicle at the union of the middle third with the medial third; fracture of the right pubic ramus; bilateral sacroiliac luxation; luxation of the atlas-occipital joint with separation of the articular surfaces; luxation of the C6-C7; fracture of the left humerus at the distal.	Severe traumatic injuries of the brain, spine and spinal cord.	Fall from high height (suicidal, from bridge)
#20 NMNHS	Neurocranium Thorax Pelvis and Lumbar Upper Extremity Lower Extremity	Crushing and sectioning of both thighs at the middle third with comminuted fracture of the femora; multiple fractures of the cranial bones; multiple fractures of all ribs; multiple fractures and sectioning of the spine and crushing of some thoracic and lumbar vertebrae; fracture of the right humerus at the middle third; comminuted fracture of both hip bones.	Severe traumatic injuries of the medulla oblongata.	Train-pedestrian accident
#21 NMNHS	-	No skeletal trauma reported.	Extensive burning and carbon monoxide poisoning.	Explosion and exposure to unspecified fire