



Published in final edited form as:

Cogn Behav Neurol. 2008 September ; 21(3): 150–156. doi:10.1097/WNN.0b013e31817720e4.

MRI Assessment of Superior Temporal Gyrus in Williams Syndrome

Adriana Sampaio, PhD^{*,†}, Nuno Sousa, MD, PhD[†], Montse Fernández, PhD^{*}, Cristiana Vasconcelos, MD[‡], Martha E. Shenton, PhD[§], and Óscar F. Gonçalves, PhD^{*}

^{*} Department of Psychology, University of Minho, Braga

[†] Life and Health Sciences Research Institute, University of Minho, Braga

[‡] Department of Neuroradiology, Hospital Geral Santo António, Porto, Portugal

[§] Psychiatry Neuroimaging Laboratory, Department of Psychiatry, Brigham and Women's Hospital, Harvard Medical School, Boston, MA

Abstract

Objective—To evaluate volumes and asymmetry of superior temporal gyrus (STG) and correlate these measures with a neurocognitive evaluation of verbal performance in Williams syndrome (WS) and in a typically developing age-matched and sex-matched group.

Background—Despite initial claims of language strength in WS, recent studies suggest delayed language milestones. The STG is implicated in linguistic processing and is a highly lateralized brain region.

Method—Here, we examined STG volumes and asymmetry of STG in WS patients and in age-matched controls. We also correlated volume of STG with a subset of verbal measures. Magnetic resonance imaging scans were obtained on a GE 1.5-T magnet with 1.5-mm contiguous slices, and were used to measure whole gray matter, white matter, and cerebrospinal fluid volumes, and also STG volume.

Results—Results revealed significantly reduced intracranial volume in WS patients, compared with controls. Right and left STG were also significantly smaller in WS patients. In addition, compared with normal controls, a lack of normal left >right STG asymmetry was evident in WS. Also of note was the finding that, in contrast to controls, WS patients did not reveal a positive correlation between verbal intelligence quotient and left STG volume, which further suggests a disruption in this region of the brain.

Conclusions—In conclusion, atypical patterns of asymmetry and reduced STG volume in WS were observed, which may, in part, contribute to some of the linguistic impairments found in this cohort of WS patients.

Keywords

Williams syndrome; STG; language; neurodevelopment

Williams syndrome (WS) is a neurodevelopmental disorder, with a prevalence of 1 in 7500,¹ and characterized by a submicroscopic deletion on chromosome 7 q11.22–23.² WS patients have an unusual phenotype, which includes a distinctive profile of physical, medical,

neurocognitive, and neuroanatomic characteristics. Typical physical characteristics include craniofacial and cardiac/pulmonary abnormalities, growth delay, hypercalcemia, hyperacusis, and feeding difficulties.³ The other main component of classic descriptions of WS phenotype is an altered neurodevelopment/cognitive profile, which consists of relative strengths and weaknesses. Specifically, initial reports of WS document a profound impairment in visuospatial processing in parallel with superior language performance (ie, “a linguistic savant”). Interestingly, much of the attraction of Williams syndrome research was fostered by this apparent dissociative pattern of neurodevelopment.⁴ However, initial reports of excelled performance in linguistics have not been reproduced in the last 2 decades and, paradoxically, impairments in narrative, syntax, morphology, phonology, and pragmatics have been observed.^{5–7}

A trend for dissociative findings in neuroimaging studies of WS patients has also been reported, and includes a general cerebral hypoplasia^{8–12} with localized gray matter reductions in parietal and occipital lobes,^{13,14} contrasting with a relative preservation of frontal and cerebellar structures, and with volume preservation of structures like the amygdala, superior temporal gyrus (STG), orbitofrontal cortex, and hippocampus.^{8,11,12,15} Several studies have also demonstrated volumetric loss in white matter, including corpus callosum.^{16–19} Cortical and thickness profile abnormalities^{20,21} with morphologic changes in central sulcus and in the Sylvian fissure^{22,23} have also been reported. Finally, abnormal patterns of cortical symmetry have recently been described in WS.²⁴

Anatomic correlates of neurologic abnormalities are, however, difficult to establish due to several technical constraints and due to the complex brain network that subserves each of the altered functions. Nonetheless, there are regions of the brain whose integrity seems to be crucial for linguistic performance; among these, is the STG. STG is a component of a frontotemporal network, including the anterior cingulate cortex, left inferior frontal gyrus, and middle temporal gyrus, that is involved in auditory processing,²⁵ being activated in word and speech processing,^{26,27} integration of lexical and syntactic integration,²⁸ and phonologic memory storage.²⁹ Besides this role in linguistic processes, STG is part of the network involved in human spatial orientation and exploration³⁰ and also social cognition,³¹ which are also extremely relevant in WS.

In the present study, we evaluated STG volume, using manual measures of magnetic resonance imaging (MRI) volume, and using automatic methods of segmentation to separate gray matter, white matter, and cerebrospinal fluid (CSF). These measures were correlated with a neurocognitive evaluation of verbal performance in WS and in a typically developing age-matched and sex-matched group.

MATERIALS AND METHODS

Participants

Study participants included 10 subjects (5 males and 5 females), diagnosed with WS [mean \pm SD age, 18.60 \pm 5.87; age range: 11 to 29 y; mean full scale intelligence quotient (IQ): 48.60 \pm 6.92]. These subjects were compared with 10 healthy control subjects individually matched for sex, age (mean \pm SD age, 19.00 \pm 5.81; age range: 11 to 29 y; mean full scale IQ: 113.22 \pm 11.41). Subjects with WS were recruited at the Genetic Medical Institute (Portugal) and the Genomic Foundation in Galicia (Spain). WS diagnoses were made by fluorescent in situ hybridization confirmation of elastin gene deletion.² Controls were typically developing individuals without evidence of psychiatric, neurologic disorder, or cognitive impairment. Each participant gave written informed consent for their participation in the study via consent forms, after a complete description of the study. Handedness was assessed through clinical

observation and was controlled for all subjects, one control subject was left-handed, and because of this was removed from the asymmetry analysis.

Neurocognitive Assessment

To assess general cognitive functioning, participants 8 to 16 years of age were administered the Wechsler Intelligence Scale for Children-Third Edition (WISCIII),³² whereas subjects over 16 years old were administered the Wechsler Adult Intelligence Scale-Third Edition (WAIS-III).³³

The Controlled Word Association Test³⁴ and Peabody Picture Vocabulary Test³⁵ were also used, Fluency test to assess verbal and phonemic fluency and receptive vocabulary. Raw scores of these assessment tests and verbal IQ were used for correlational analyses with brain volumetric measures. Neurocognitive tests were in the native language of the patients and were administered and scored accordingly.

MRI Acquisition and Processing

MR images were obtained on a 1.5-T General Electric system (GE Medical Systems). The scans acquisition protocol consisted of contiguous 1.5-mm coronal T1 (Spoiled gradient-SPGR) slices of the whole brain and an axial PD/T2 sequence (proton density and T2-weighted). The parameters used were echo time: 5.0 ms, repetition time: 35 ms, flip angle: 45 degrees, acquisition matrix: 256 × 192, voxel dimensions: 9375 × 0.9374 × 1.5 mm). Images were aligned by using the line between the anterior and posterior commissures and the sagittal sulcus to correct head tilt and were also resampled to make isotropic voxels (0.9375mm³, cubic interpolation). Then, an atlas-based expectation maximization segmentation program separated raw MR data into CSF, gray matter (including cortical and cerebellar cortices, basal ganglia, and hippocampal-amygdala complex), and white matter.³⁶ Total intracranial volume (TIV) was the sum of gray matter, white matter, and CSF volumes and relative volumes were obtained by dividing absolute volumes by ICV.

Regions of Interest

Cortical STG was outlined manually using the 3D Slicer Software (<http://www.slicer.org/>) in the realigned images. To define STG (right and left hemispheres), we used the same methods and landmarks previously used to outline this region of interest.³⁷ Briefly, the anterior limit of STG was identified as the first slice showing the white matter tract (temporal stem) connecting the temporal lobe with the base of the brain. The posterior boundary of STG was defined as the slice where the fibers of the crux of the fornix last appeared (Fig. 1). Two raters, blind to study hypothesis, and blind to diagnostic group, measured both STG for all subjects with an interrater reliability >0.90. A relative measure of STG was computed as the ratio between STG volume and total gray matter volume. Asymmetry index of STG was computed according to the following expression: $(L-R)/0.5(L+R)$, where L and R refer to left and right hemispheres.

Data Analysis

All volumetric data met the criteria for the use of parametric tests, including normality (Kolmogorov-Smirnov and Shapiro-Wilk tests) and variance homogeneity (Levene test). A repeated-measure analysis of variance was used to determine STG volume differences between the WS and control subjects. Thus, diagnosis (WS and controls) was used as the between-subject factor and hemispheric side (left vs. right) as the within factor. If a main effect for group was found, then a Student *t* test was used to test the mean difference between groups. A *P* value less than 0.05 was assumed to denote a significant difference. Spearman rank correlations were used to correlate brain volumes with neurocognitive measures in WS and controls separately, because of the non-normality of the neurocognitive measures.

RESULTS

There was no significant group differences with respect to sociodemographic characteristics, including age [$t(18) = -0.153, P > 0.05$], and socioeconomic status-Graffar index ($Z = -0.932; P > 0.05$), although they differ in level of education ($Z = -2.160, P = 0.031$) (data shown in Table 1).

Overall Intracranial Volumes

Table 2 shows TIV for WS, revealing an absolute reduction of 17.7% compared with the normal control group. Indeed, WS subjects show absolute values of gray matter [$t(18) = -3.297, P < 0.01$], white matter [$t(18) = -3.060, P < 0.01$], and CSF [$t(18) = -4.183, P < 0.01$] volumes that were significantly reduced compared with controls. As a consequence, TIV was significantly reduced in the clinical group [$t(18) = -4.359, P < 0.001$].

When relative volume was estimated (ie, ratio between tissue volume and TIV), no significant differences were found for white matter volume [$t(18) = -0.709, P > 0.05$, effect size = -1.37]. However, gray matter volume [$t(18) = 2.222, P < 0.05$, effect size = -1.47] was significantly increased and CSF volume [$t(18) = -2.622, P < 0.05$, effect size = -1.87] (Table 2) was significantly reduced.

Figure 2 shows the main results obtained for STG, in right and left hemispheres. Repeated-measures analysis of variance of absolute volumes revealed a significant difference, showing main effect of side (left vs. right) [$F(1,18) = 4.983, P = 0.039$], diagnosis [$F(1,18) = 6.301, P = 0.022$], and an interaction between side and diagnosis [$F(1,18) = 14.992, P = 0.001$]. Follow-up t test showed that absolute STG volumes were significantly reduced in WS, when comparing with control group, both in the right hemisphere [$t(18) = -2.845, P < 0.05$, effect size = -1.34] and in the left hemisphere [$t(18) = -2.117, P < 0.05$, effect size = -1.52]. However, when relative volumes of STG were computed (ratio between STG volume and total gray matter volume), a marginal side effect [$F(1,18) = 4.627, P = 0.045$] and an interaction between side and diagnosis was found [$F(1,18) = 15.436, P = 0.013$]. No diagnosis effect was found [$F(1,18) = 0.215, P = 0.648$]. Indeed, t tests yielded no statistical significant difference between the 2 groups, for either right hemisphere [$t(18) = 0.031, P = 0.976$, effect size = -0.11] or left hemisphere [$t(18) = -0.918, P = 0.371$, effect size = -0.37] (Fig. 2B).

We next analyzed the cortical asymmetry between left-right STG (Table 3). WS subjects demonstrate a lack of asymmetry, compared with the normal left>right STG asymmetry observed in the control group [$t(17) = -5.219, P < 0.001$].

Correlational analysis between neurocognitive performance and neuroanatomic measures revealed a statistically positive correlation between verbal IQ and left STG volume ($r_{sp} = 0.706, P < 0.05$) in the control group (Figs. 3A, B and Table 4). Of note, in the WS group, left STG volume was not correlated with verbal IQ ($r_{sp} = 0.085, P = 0.815$) or any other neurocognitive measure.

DISCUSSION

The present study confirms an overall reduction in brain volumes in WS patients, including also a reduction in overall gray matter, white matter, and CSF compared with controls. Most importantly, this reduction was found to be disproportionate. That is, when relative volumes were computed, the WS patients showed a gray matter volume increase, in parallel with a decrease in CSF volumes. In contrast to neurodegenerative disorders, in which brain parenchyma atrophy is associated with increased CSF spaces,³⁸ a reduction in CSF volume in WS subjects was found, compared with normal controls. That is, our data seem to point to the

fact that TIV reduction in WS may be explained mainly by white matter and CSF volume reduction. These results are in accordance with previous reports by Reiss and colleagues,^{11, 12} but also with other studies providing indirect evidence of a relative increase in gray matter volume, including reports of regional increases in cortical thickness.²¹

The volumetric changes of gray and white matter evident in WS are likely to reflect their distinct developmental trajectories from normal development. Decreases in cortical gray matter densities are observed in adolescence and adulthood, being more prominent in dorsal cortical regions.^{39,40} Conversely, white matter volume increases linearly with age.^{39,41–43} Furthermore, better cognitive performance has been associated with a coherent and myelinated white matter circuitry, particularly in prefrontal cortex.⁴¹

Our findings in WS are also interesting in light of findings that demonstrate that brain processes like synaptic pruning and myelination occur concomitantly in the developing brain, resulting in a gray matter decrease (or cortical thickness reduction) and white matter increases.⁴⁰ These brain processes also shape cognitive development⁴⁴ and are likely altered in WS.

We also note that preservation of STG in WS patients, reported in the current study, differs from the relative increase of STG (if computed in a ratio of STG/total brain volume) reported by Reiss and coworkers.¹² These authors interpreted their findings as possibly explaining the dissociate neurodevelopmental profile of WS patients, namely the relative sparing of music and language processing. However, this notion of spared language abilities was further challenged and subsequent studies demonstrated that linguistic function in WS is not only delayed in acquisition, but also impaired in adolescence/adulthood^{45–47} suggesting that verbal and nonverbal abilities are equally impaired in WS.⁴⁸ Indeed, abnormal grammatical (syntactical and morphosyntactic), lexico-semantic, and pragmatic processes were found in this syndrome.^{6,7,49} Also, pragmatic and communicational difficulties have been described, with WS patients showing impairments in conversation skills, namely, production of a “cocktail party speech,” discourse incoherence, stereotyped conversation, and difficulties at initiating and developing conversational rapport (eg, understanding the emotional and cognitive states of the interlocutor). This is evident both within a conversation context and during structured tasks (eg, interpreting metaphoric and nonliteral language and during narrative tasks).^{5,50–53} Moreover, these deficits are corroborated by parents reports, who indicate impairments in all dimensions of language.^{48,51}

Also, the reduction of STG absolute volumes observed in this study is consistent with linguistic deficits found in this cohort of WS subjects.^{5,53} In fact, the explanation for the discrepancy between our neuroanatomic results and those previously reported¹² might be reflected in the neuropsychologic differences in the populations under study. Indeed, in contrast with other studies,¹⁵ in our cohort of WS patients, general cognitive deficits paralleled impaired linguistic/narrative performance.⁵

Interestingly, the positive correlation between left cortical STG volumes with verbal IQ found in normal subjects was not present in WS subjects. This fact reinforces the view that STG decreased volumes found in WS subjects may underlie their language impairments. Additional studies (eg, with functional MRI) are, however, needed to establish the functional impairment of this brain structure in WS.

Another finding of interest in the current study is the lack of normal asymmetry in STG in our WS patients. More Specifically, subjects with left hemispheric dominance and normal psychomotor development are known to exhibit a high asymmetry degree, characterized by left>right STG volume.^{54,55} Interestingly, this asymmetry was not observed in our cohort of WS subjects, which is consistent with reports of an elevated bilateral symmetry²⁴ and a lack of asymmetry in left planum temporale in WS.²² Histologic studies also provide evidence of

this lack of asymmetry in WS.^{56,57} Importantly, atypical patterns of structural and functional asymmetries were also shown in patients suffering from neuro developmental disorders such as schizophrenia^{37,58} and dyslexia.^{59,60} In schizophrenic patients, the leftward asymmetry is much reduced due possibly to a relatively larger right planum temporale than normal controls.⁶¹

Structural and functional asymmetries are characteristic of biologic systems and are associated with lateralization and cognitive skills, even in invertebrates.⁶² Thus, the lack of asymmetry observed in this clinical population is additional evidence to suggest that structural alterations in STG morphology are likely associated with abnormal brain development and language impairments.

In conclusion, the present study reveals that absolute STG volume, though not relative STG volume, is reduced in WS, a finding associated with impaired verbal IQ. In parallel, we also found a loss of the normal left>right asymmetry in STG in WS patients that was not evident in normal controls. These findings, taken together, strongly suggest that abnormal development of STG underlies the cognitive and linguistic phenotype of WS. Also, these data support the need to consider language and speech therapy in the multidisciplinary intervention approaches with these patients, namely intervention in the area of pragmatics, grammar, and also the design of specific intervention strategies to improve prelinguistic development.^{47,63}

Future studies are needed to more closely evaluate the implications of structural and functional brain anomalies in WS, coupled with possible genetic variations that have further implications for both structural and functional brain anomalies in this disorder.

Acknowledgments

Supported by the grants POCTI/PSI/58364/2004 and SFRH/BD/16091/2004 from Fundação para a Ciência e Tecnologia (Portugal). Also supported, in part, by grants from the National Institutes of Health (K05 MH 01110).

References

1. Stromme P, Bjornstad PG, Ramstad K. Prevalence estimation of Williams syndrome. *J Child Neurol* 2002;17:269–271. [PubMed: 12088082]
2. Korenberg JR, Chen XN, Hirota H, et al. VI. Genome structure and cognitive map of Williams syndrome. *J Cognit Neurosci* 2000;12(suppl 1):89–107. [PubMed: 10953236]
3. Metcalfe K. Williams syndrome: an update on clinical and molecular aspects. *Arch Dis Childhood* 1999;81:198–200. [PubMed: 10451389]
4. Bellugi U, Bihrlle A, Jernigan T, et al. Neuropsychological, neurological, and neuroanatomical profile of Williams syndrome. *Am J Med Gen Suppl* 1990;6:115–125.
5. Gonçalves OF, Pérez A, Henriques M, et al. Funcionamento Cognitivo e Produção Narrativa no Síndrome de Williams: Congruência ou Dissociação Neurocognitiva? *Int J Clin Health Psychol* 2004;4:623–638.
6. Karmilo-Smith A, Brown JH, Grice S, et al. Dethroning the myth: cognitive dissociations and innate modularity in Williams syndrome. *Dev Neuropsychol* 2003;23:227–242. [PubMed: 12730026]
7. Brock J. Language abilities in Williams syndrome: a critical review. *Dev Psychopathol* 2007;19:97–127. [PubMed: 17241486]
8. Chiang MC, Reiss AL, Lee AD, et al. 3D pattern of brain abnormalities in Williams syndrome visualized using tensor-based morphometry. *Neuroimage* 2007;36:1096–1109. [PubMed: 17512756]
9. Jernigan TL, Bellugi U. Anomalous brain morphology on magnetic resonance images in Williams syndrome and Down syndrome. *Arch Neurol* 1990;47:529–533. [PubMed: 2139774]
10. Jernigan TL, Bellugi U, Sowell E, et al. Cerebral morphologic distinctions between Williams and Down syndromes. *Arch Neurol* 1993;50:186–191. [PubMed: 8431138]

11. Reiss AL, Eckert MA, Rose FE, et al. An experiment of nature: brain anatomy parallels cognition and behavior in Williams syndrome. *J Neurosci* 2004;24:5009–5015. [PubMed: 15163693]
12. Reiss AL, Eliez S, Schmitt JE, et al. IV. Neuroanatomy of Williams syndrome: a high-resolution MRI study. *J Cognit Neurosci* 2000;12(suppl 1):65–73. [PubMed: 10953234]
13. Boddaert N, Mochel F, Meresse I, et al. Parieto-occipital grey matter abnormalities in children with Williams syndrome. *Neuroimage* 2006;30:721–725. [PubMed: 16380272]
14. Eckert MA, Hu D, Eliez S, et al. Evidence for superior parietal impairment in Williams syndrome. *Neurology* 2005;64:152–153. [PubMed: 15642924]
15. Meyer-Lindenberg A, Mervis CB, Sarpal D, et al. Functional, structural, and metabolic abnormalities of the hippocampal formation in Williams syndrome. *J Clin Invest* 2005;115:1888–1895. [PubMed: 15951840]
16. Luders E, Di Paola M, Tomaiuolo F, et al. Callosal morphology in Williams syndrome: a new evaluation of shape and thickness. *Neuroreport* 2007;18:203–207. [PubMed: 17314657]
17. Schmitt JE, Eliez S, Bellugi U, et al. Analysis of cerebral shape in Williams syndrome. *Arch Neurol* 2001;58:283–287. [PubMed: 11176967]
18. Schmitt JE, Eliez S, Warsofsky IS, et al. Corpus callosum morphology of Williams syndrome: relation to genetics and behavior. *Dev Med Child Neurol* 2001;43:155–159. [PubMed: 11263684]
19. Tomaiuolo F, Di Paola M, Caravale B, et al. Morphology and morphometry of the corpus callosum in Williams syndrome: a T1-weighted MRI study. *Neuroreport* 2002;13:2281–2284. [PubMed: 12488811]
20. Kippenhan JS, Olsen RK, Mervis CB, et al. Genetic contributions to human gyrification: sulcal morphometry in Williams syndrome. *J Neurosci* 2005;25:7840–7846. [PubMed: 16120786]
21. Thompson PM, Lee AD, Dutton RA, et al. Abnormal cortical complexity and thickness profiles mapped in Williams syndrome. *J Neurosci* 2005;25:4146–4158. [PubMed: 15843618]
22. Eckert MA, Galaburda AM, Karchemskiy A, et al. Anomalous sylvian fissure morphology in Williams syndrome. *Neuroimage* 2006;33:39–45. [PubMed: 16876437]
23. Jackowski AP, Schultz RT. Foreshortened dorsal extension of the central sulcus in Williams syndrome. *Cortex* 2005;41:282–290. [PubMed: 15871594]
24. Van Essen DC, Dierker D, Snyder AZ, et al. Symmetry of cortical folding abnormalities in Williams syndrome revealed by surface-based analyses. *J Neurosci* 2006;26:5470–5483. [PubMed: 16707799]
25. Martin RC. Language processing: functional organization and neuroanatomical basis. *Annu Rev Psychol* 2003;54:55–89. [PubMed: 12359917]
26. Boatman D. Cortical bases of speech perception: evidence from functional lesion studies. *Cognition* 2004;92:47–65. [PubMed: 15037126]
27. Constable RT, Pugh KR, Berroya E, et al. Sentence complexity and input modality effects in sentence comprehension: an fMRI study. *Neuroimage* 2004;22:11–21. [PubMed: 15109993]
28. Grodzinsky Y, Friederici AD. Neuroimaging of syntax and syntactic processing. *Curr Opin Neurobiol* 2006;16:240–246. [PubMed: 16563739]
29. Demonet JF, Thierry G, Cardebat D. Renewal of the neurophysiology of language: functional neuroimaging. *Physiol Rev* 2005;85:49–95. [PubMed: 15618478]
30. Himmelbach M, Erb M, Karnath HO. Exploring the visual world: the neural substrate of spatial orienting. *Neuroimage* 2006;32:1747–1759. [PubMed: 16806986]
31. Pelphrey KA, Viola RJ, McCarthy G. When strangers pass: processing of mutual and averted social gaze in the superior temporal sulcus. *Psychol Sci* 2004;15:598–603. [PubMed: 15327630]
32. Wechsler, D. Wechsler Intelligence Scale for Children Manual. Vol. 3. San Antonio: Psychological Corporation; 1991.
33. Wechsler, D. Wechsler Adult Intelligence Scale Manual. Vol. 3. San Antonio: Psychological Corporation; 1997.
34. Benton, AL.; Hamsher, KD. Multilingual Aphasia Examination. Iowa: University of Iowa; 1989.
35. Dunn, LM.; Dunn, LM. Peabody Picture Vocabulary Test-Revised. Circle Pines, MN: American Guidance Services; 1981.

36. Pohl K, Bouix S, Kikinis R. Anatomical guided segmentation with nonstationary tissue class distributions in an expectation-maximization framework. *IEEE Int Symp Biomed Imaging* 2004;81–84.
37. Shenton ME, Kikinis R, Jolesz FA, et al. Left-lateralized temporal lobe abnormalities in schizophrenia and their relationship to thought disorder: a computerized, quantitative MRI study. *New Engl J Med* 1992;327:604–612. [PubMed: 1640954]
38. Tanabe JL, Amend D, Schu N, et al. Tissue segmentation of the brain in Alzheimer disease. *Am J Neuroradiol* 1997;18:115–123. [PubMed: 9010529]
39. Giedd JN, Blumenthal J, Jeffries NO, et al. Brain development during childhood and adolescence: a longitudinal MRI study. *Nat Neurosci* 1999;2:861–863. [PubMed: 10491603]
40. Sowell ER, Thompson PM, Toga AW. Mapping changes in the human cortex throughout the span of life. *Neuroscientist* 2004;10:372–392. [PubMed: 15271264]
41. Barnea-Goraly N, Menon V, Eckert M, et al. White matter development during childhood and adolescence: a cross-sectional diffusion tensor imaging study. *Cereb Cortex* 2005;15:1848–1854. [PubMed: 15758200]
42. Matsuzawa J, Matsui M, Konishi T, et al. Age-related volumetric changes of brain gray and white matter in healthy infants and children. *Cereb Cortex* 2001;11:335–342. [PubMed: 11278196]
43. Reiss AL, Abrams MT, Singer HS, et al. Brain development, gender and IQ in children. A volumetric imaging study. *Brain* 1996;119 (Pt 5):1763–1774. [PubMed: 8931596]
44. Sowell ER, Thompson PM, Leonard CM, et al. Longitudinal mapping of cortical thickness and brain growth in normal children. *J Neurosci* 2004;24:8223–8231. [PubMed: 15385605]
45. Stevens T, Karmilo-Smith A. Word learning in a special population: do individuals with Williams syndrome obey lexical constraints? *J Child Lang* 1997;24:737–765. [PubMed: 9519593]
46. Thomas MSC, Dockrell J, Messer D, et al. Speeded naming, frequency and the development of the lexicon in Williams syndrome. *Lang Cognit Process* 2006;21:721–759.
47. Semel, SR.; Rosner, E. *Understanding Williams Syndrome: Behavioral Patterns and Interventions*. Mahwah, NJ: Lawrence Erlbaum Associates; 2003.
48. Greer MK, Brown FR, Pai GS, et al. Cognitive, Adaptive, and Behavioral Characteristics of Williams Syndrome. *Am J Med Genet* 1997;74:521–525. [PubMed: 9342204]
49. Karmilo-Smith A, Grant J, Berthoud I, et al. Language and Williams syndrome: how intact is “intact”? *Child Dev* 1997;68:246–262. [PubMed: 9180000]
50. Davies M, Udwin O, Howlin O. Adults with Williams syndrome. Preliminary study of social, emotional and behavioural difficulties. *Br J Psychiatry* 1998;172:273–276. [PubMed: 9614479]
51. Laws G, Bishop DVM. Pragmatic language impairment and social deficits in Williams syndrome: a comparison with Down’s syndrome and specific language impairment. *Int J Lang Commun Disord* 2004;39:45–64. [PubMed: 14660186]
52. Stojanovik V. Social interaction deficits and conversational inadequacy in Williams syndrome. *J Neurolinguistics* 2006;19:157–173.
53. Garayzabal Heinze E, Prieto MF, Sampaio A, et al. Cross-linguistic assessment of verbal production from a narrative task in Williams Syndrome. *Psicothema* 2007;19:428–434. [PubMed: 17617981]
54. Geschwind N, Levitsky W. Human brain: left-right asymmetries in temporal speech region. *Science* 1968;161:186–187. [PubMed: 5657070]
55. Toga AW, Thompson PM. Mapping brain asymmetry. *Nat Rev Neurosci* 2003;4:37–48. [PubMed: 12511860]
56. Galaburda AM, Bellugi UV. Multi-level analysis of cortical neuroanatomy in Williams syndrome. *J Cognit Neurosci* 2000;12(suppl 1):74–88. [PubMed: 10953235]
57. Holinger DP, Bellugi U, Mills DL, et al. Relative sparing of primary auditory cortex in Williams Syndrome. *Brain Res* 2005;1037:35–42. [PubMed: 15777750]
58. Barta PE, Pearlson GD, Powers RE, et al. Auditory hallucinations and smaller superior temporal gyral volume in schizophrenia. *Am J Psychiatry* 1990;147:1457–1462. [PubMed: 2221156]
59. Galaburda AM, Sherman GF, Rosen GD, et al. Developmental dyslexia: four consecutive patients with cortical anomalies. *Ann Neurol* 1985;18:222–233. [PubMed: 4037763]

60. Larsen JP, Høien T, Lundberg I, et al. MRI evaluation of the size and symmetry of the planum temporale in adolescents with developmental dyslexia. *Brain Lang* 1990;39:289–301. [PubMed: 2224496]
61. Barta PE, Pearlson GD, Brill LB II, et al. Planum temporale asymmetry reversal in schizophrenia: replication and relationship to gray matter abnormalities. *Am J Psychiatry* 1997;154:661–667. [PubMed: 9137122]
62. Pascual A, Huang KL, Neveu J, et al. Neuroanatomy: brain asymmetry and long-term memory. *Nature* 2004;427:605–606. [PubMed: 14961111]
63. Fidler DJ, Philofsky A, Hepburn SL. Language phenotypes and intervention planning: bridging research and practice. *Ment Retard Dev Disabil Res Rev* 2007;13:47–57. [PubMed: 17326117]

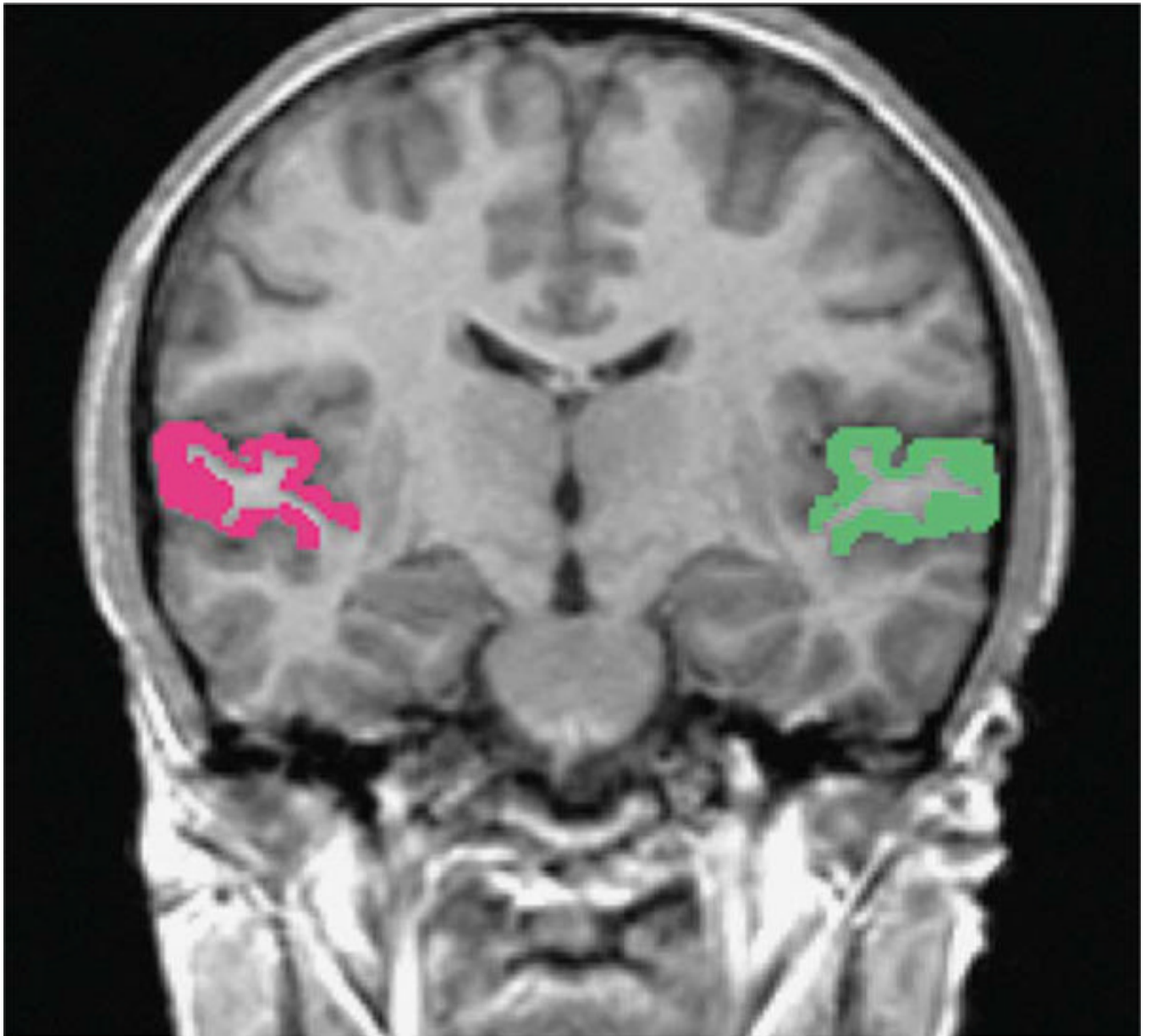
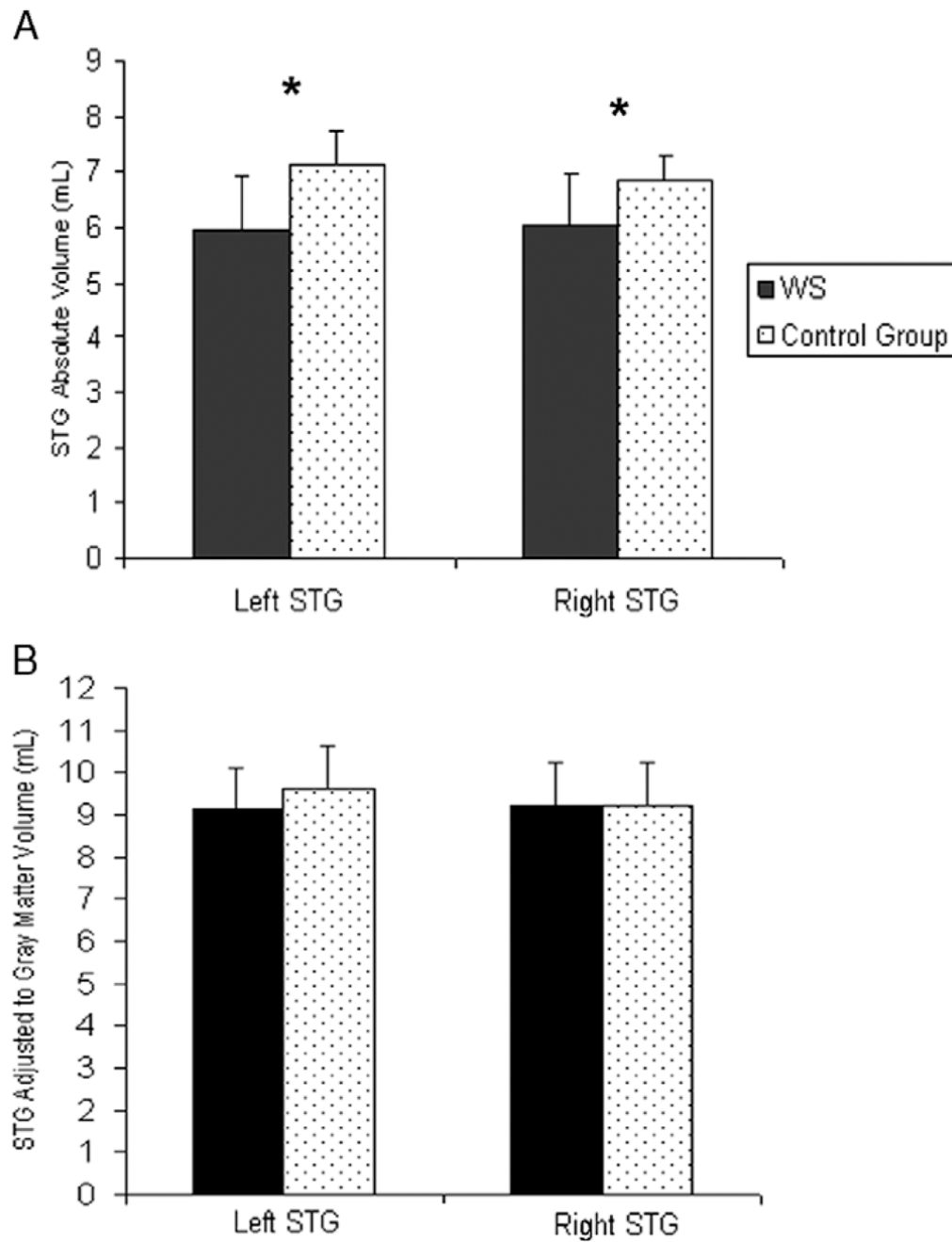


FIGURE 1.
Superior temporal gyrus manual segmentation.

**FIGURE 2.**

A, STG absolute volumes (right and left) in WS and control group. B, Adjusted STG to gray matter volume (left and right) in WS and control group; $*P < 0.05$. STG indicates superior temporal gyrus; WS, Williams syndrome.

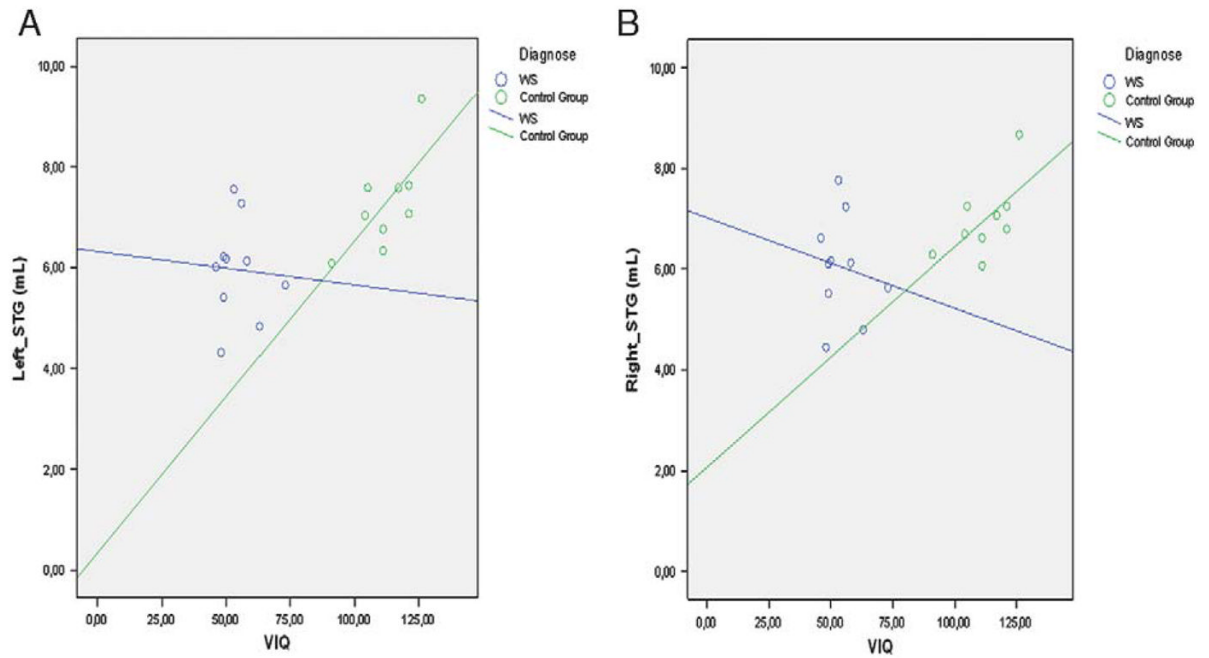


FIGURE 3.

Scatter dot of Verbal and left STG volume (A) and right STG volume (B). VIQ indicates Verbal Intelligence Quotient; STG, superior temporal gyrus.

TABLE 1

Sociodemographic Characteristics

	WS (N = 10)		Control Group (N = 10)	
	M (SD)	Range	M (SD)	Range
Age	18.60 (5.87)	11–29	19.00 (5.81)	11–29
Full scale IQ	48.60 (6.92)	40–61	113.22 (11.41)	90–124
Level of education	Mdn 9	6–9	Mdn 12	6–15
Socioeconomical status (Graffar index)	3	1–4	3	1–4
Sex				
Male	5	50%	5	50%
Female	5	50%	5	50%

IQ indicates intelligence quotient; Mdn, median; WS, Williams syndrome.

Absolute and Relative Volumes of Gray Matter, White Matter, and Cerebrospinal Fluid in WS and Control Group

Volume (mL)	WS (N = 10)		Control Group (N = 10)		t (18)	P
	M	SD	M	SD		
TIV	1186.717	130.652	1441.322	130.588	-4.359	$P < 0.001$
Gray matter Absolute*	655.702	70.121	746.370	51.423	-3.297	$P < 0.01$
Relative*	553.772	39.512	519.339	28.990	2.222	$P < 0.05$
White matter Absolute*	396.809	77.357	494.177	64.374	-3.060	$P < 0.01$
Relative*	332.804	36.244	341.915	18.314	-0.709	$P = 0.487$
CSF Absolute*	134.204	22.595	200.774	44.975	-4.183	$P < 0.01$
Relative*	113.424	17.291	138.747	25.168	-2.622	$P < 0.05$

* $\times 10^{-3}$.

CSF indicates cerebrospinal fluid; TIV, total intracranial volume; WS, Williams syndrome.

TABLE 3

STG Left-Right Asymmetry Degree in WS and Control Group

	WS Group (N = 10)		Control Group (N = 9)		t (17)	P
	M	SD	M	SD		
Left-right asymmetry in STG	0.988	0.317	1.050	0.175	-5.219	P < 0.001

STG indicates superior temporal gyrus; WS, Williams syndrome

TABLE 4

Correlations Between Neurocognitive Measures and STG volumes

	Left STG	Right STG	Asymmetry Index
VIQ			
WS	0.085	-0.006	0.565
NG	0.706*	0.647	0.386
FAS-letters			
WS	0.058	0.290	-0.493
NG	-0.429	-0.393	-0.086
FAS-animals			
WS	0.348	0.174	0.319
NG	0.505	0.595	-0.257
Peabody			
WS	0.321	0.320	0.286
NG	0.679	0.714	0.600

* $P < 0.05$.

FAS indicates Fluency test; NG, normal group; STG, superior temporal gyrus; VIQ, verbal intelligence quotient; WS, Williams syndrome.